

The ins and outs of ostomy management



Take away the confusion about types of ostomies and patient education with case studies on colostomy, ileostomy, and urostomy.

By Donna Scemons, PhD, FNP-BC, CNS, CWOCN
President and Family Nurse Practitioner • Healthcare Systems, Inc. • Castaic, Calif.
Assistant Professor and Coordinator of Family Nurse Practitioner Program
California State University • Los Angeles, Calif.



2.3
ANCC
CONTACT HOURS

Ostomy, stoma, colostomy, ileostomy, urostomy, or ileal conduit? Even if these terms are clear to you, they're confusing for many patients and family members. In this article, we'll walk through three patient examples of colostomy, ileostomy, and urostomy—surgical procedures involving diversion of either fecal matter or urine through a stoma located in the abdominal wall—to help you educate hospitalized patients after surgery so they're prepared to care for their ostomy after discharge. See *Sorting out ostomies* and *Colostomy and ileostomy care* for additional information about location, etiology, effluent, and permanence by type of ostomy.

Caring for a patient with a colostomy

Ms. G, a 67-year-old Black American, is a retired teacher. Her mother, father, and an older brother were treated for breast and/or bowel cancer and died of their disease. All adults in Ms. G's family smoked cigarettes and consumed a diet high in fat and red or processed meat and low in fiber. She quit a two pack/day habit at age 57 when her first grandchild was born.

Although Ms. G previously had regular bowel habits, for the past 6 months she's had an elimination pattern of narrow stools followed by constipation and then diarrhea.

A fecal occult blood test was positive at her annual physical exam 2 weeks ago. Diagnostic testing revealed a lesion in the sigmoid colon. Her surgeon suspects she has colon cancer.

Other diseases or conditions that may lead to a colostomy are Crohn disease, intestinal obstruction, perforated diverticula or abscess, intestinal or rectal trauma, rectovaginal fistula, Hirschsprung disease, imperforate anus, necrotizing enterocolitis or other birth defects, and functional constipation.

Ms. G is scheduled for surgery to remove the lesion and will most likely return from surgery with a colostomy. This means that the colon will be diverted somewhere along its 5 ft (1.5 m) to form a stoma through the abdominal wall. Asking for a more precise post-op report will provide the colostomy location and allow for the most effective care plan and patient education. When a malignancy has been removed from the colon, the colostomy is usually located in the sigmoid colon. For patients with more advanced disease, however, the surgeon may fashion the colostomy in another section of the colon. The location of the colostomy determines to a large extent the consistency and frequency of the effluent.

Sorting out ostomies

Type of ostomy and location	Etiology	Effluent type	Temporary or permanent?
COLOSTOMY			
Sigmoid colostomy Lower left abdomen	<ul style="list-style-type: none"> • Cancer of the rectum or sigmoid colon (most common) • Bowel obstruction • Congenital defects • Paralysis • Trauma 	Soft to firm and formed	Usually permanent, but may be temporary in some cases of abdominal trauma and/or diverticulitis
Descending colostomy Lower left abdomen	<ul style="list-style-type: none"> • Cancer of the rectum or sigmoid colon • Bowel obstruction • Congenital defects • Diverticulitis • Paralysis • Trauma 	Soft, semiformal to formed	Usually permanent, but depends on etiology and the patient's clinical condition
Transverse colostomy Upper abdomen, middle or right side	<ul style="list-style-type: none"> • Birth defects • Bowel obstruction • Cancer (descending or sigmoid colon) • Diverticulitis • Paralysis • Trauma 	Semiformed; few digestive enzymes present; unpredictable	Depends on etiology
Ascending colostomy Right abdomen	<ul style="list-style-type: none"> • Colon cancer, usually right-sided tumors • Rarely done because ileostomy is preferable 	Semiliquid to liquid; contains highly acidic digestive enzymes	Usually permanent, but depends on etiology, the rationale for ostomy creation, and the patient's general condition
Loop colostomy Usually in the transverse colon with proximal (effluent) and distal (mucus) stoma; upper abdomen, middle or right side; patient may pass mucus rectally	<ul style="list-style-type: none"> • Trauma • More easily done in emergency situations 	Semiformed; few digestive enzymes present; mucus from the second stoma	Usually temporary, but depends on etiology and the patient's general health, clinical condition, and the rationale for stoma creation
Double-barrel colostomy Proximal and distal stoma; distal is mucus fistula	<ul style="list-style-type: none"> • Cancer of the rectum or sigmoid colon • Bowel obstruction • Diverticulitis • Trauma 	Semiformed; few digestive enzymes present; mucus from the second stoma	Usually temporary but depends on etiology, the patient's general health, clinical condition, and the rationale for stoma creation
ILEOSTOMY			
Ileostomy Lower right abdomen is most common, but may also be placed in the lower left abdomen; dependent on surgical findings, abdominal condition such as scars, and surgeon's preference	<ul style="list-style-type: none"> • Ulcerative colitis • Familial polyposis • Crohn disease 	Liquid; contains high number of digestive enzymes	Depends on etiology; may be used as a fecal diversion; if the patient is being prepared for an ileoanal anastomosis, the ileostomy is temporary for several weeks before the second surgery to create the internal pouch

continued

Ileoanal anastomosis (also known as J-pouch, pull-through, or pelvic pouch) Usually in the lower right abdomen; the patient must have an intact, disease free anus; the bowel is surgically attached to the anus and the patient doesn't wear an ostomy appliance	<ul style="list-style-type: none"> • Ulcerative colitis • Familial polyposis 	Liquid to soft stool; high number of digestive enzymes; initially until the pouch is sufficiently stretched, the patient will have 8 to 10 stools/day; after the pouch is stretched, bowel movements may be reduced to 4 to 6/day	Usually permanent
Continent ileostomy (also known as Kock pouch or Barnett continent ileal reservoir) An option when there's damage or disease in the rectum and/or anus	<ul style="list-style-type: none"> • Bowel diversion surgeries: ileostomy, colostomy, ileoanal reservoir 	Liquid to paste-like; contains higher number of digestive enzymes than a colostomy	Usually permanent
UROSTOMY			
Urostomy Usually in the lower right abdomen	<ul style="list-style-type: none"> • Bladder cancer • Neurologic dysfunction of bladder • Birth defects • Chronic bladder inflammation 	Continuous urine and some mucus	Usually permanent
Ureterostomy (rarely done) Surgical placement of ureters directly to the right and left abdomen; requires two appliances (one for each stoma)	<ul style="list-style-type: none"> • Bladder cancer • Neurologic dysfunction of bladder • Birth defects • Chronic bladder inflammation 	Continuous urine and some mucus	Temporary or permanent depending on etiology and the patient's general health
Ileal conduit Usually in the lower right abdomen	<ul style="list-style-type: none"> • Bladder cancer • Neurologic dysfunction of bladder • Birth defects • Chronic bladder inflammation • Radiation injuries • Spinal cord injury 	Continuous urine and some mucus	Usually permanent
Continent urostomy (also known as Kock pouch or Indiana pouch) In thin patients, more midline above pubic hair; placed higher in older adults or obese patients	<ul style="list-style-type: none"> • Bladder cancer • Gynecologic cancer • Neurologic dysfunction of bladder • Birth defects 	Urine through straight catheterization every 4 to 6 hours	Usually permanent
Bladder substitute An internal pouch is surgically created to which ureters are attached; there's no stoma, the patient urinates through the urethra	<ul style="list-style-type: none"> • Bladder cancer • Gynecologic cancer 	Urine through the urethra	Usually permanent

Colostomy and ileostomy are used to divert fecal matter.



In Ms. G's case, the colostomy is located in the sigmoid colon, so her stoma is located on the left side of the abdomen. Postoperatively, gas followed by effluent from a colostomy will generally start on the third to fifth day. Initially, it may be more liquid and dark red to brown with a mucus consistency as the bowel rids itself of old blood and mucus. After Ms. G resumes her usual activities, the effluent will likely be the consistency of a semisolid thick paste or more formed. If she had regular and routine bowel movements before developing cancer, Ms. G may experience more regular effluent with a sigmoid colostomy.

Ms. G's healthcare provider may prescribe colostomy irrigation to assist in regulating the effluent. How long the patient remains in acute care and whether irrigation is prescribed depends on the surgeon. If irrigation is prescribed, it may first be performed at home with the assistance of a home healthcare nurse, depending on how long the patient stays in acute care. This nurse may or may not also be a wound, ostomy, and continence (WOC) nurse. Colostomy irrigation may also be taught by nurses in long-term-care facilities.

Irrigation is performed by administering an enema through the colostomy using a colostomy irrigation set rather than an enema set. Ms. G's nurse discusses the rationale for colostomy irrigation—the colostomy produces effluent with no natural control of the outflow—and teaches her how to perform the procedure.

Ms. G's nurse educates her about caring for her stoma, as well as selecting and caring for the appliances or pouches. The appliance or pouch with which Ms. G leaves surgery will be used for the first few days or even the first week. During this time, the skin barrier or wafer should be changed every 3 to 5 days or as needed if leaking occurs.

Patient education includes information about cleaning the peristomal skin with tepid water alone or with a mild, nondrying soap. The skin must be patted dry with a

clean dry tissue or cloth before the skin barrier is placed to ensure it sticks and prevents leaking.

A key point the nurse discusses with Ms. G is that any leaking requires a complete change of equipment—down to the skin—because a leak can't be patched. The opening in the skin barrier should be fitted around the stoma with $\frac{1}{16}$ - to $\frac{1}{8}$ -in distance between the stoma and the barrier.

Her nurse also educates Ms. G about the stoma: As a part of her intestine, it should generally be the same color as the tissue in her mouth. Because it's a mucous membrane, the stoma has no nerve endings and should always be moist. The stoma may bleed occasionally; this isn't unusual unless bleeding is active (consistent and doesn't stop). If the bleeding doesn't stop, Ms. G should immediately notify her healthcare provider.

Ms. G needs to learn how and when to empty the pouch. The nurse tells her that whenever the pouch is one-third to half full, she should empty it by releasing the tail closure while sitting on the toilet. There are various tail closures in use today, so education depends on the type of closure. Emptying the pouch helps prevent leaking from the weight of the effluent pulling the barrier away from the skin.

If the patient has an intestinal obstruction, intestinal or rectal trauma, a rectovaginal fistula, a perforated diverticula or abscess, or certain cancers of the colon, the colostomy may be temporary rather than permanent. In some cases, when the surgeon determines that the bowel has healed, a reversal or takedown surgery may be scheduled. Although this procedure is considered surgery, the time in the OR and in post-op recovery is usually significantly less than for a colostomy.

Caring for a patient with an ileostomy

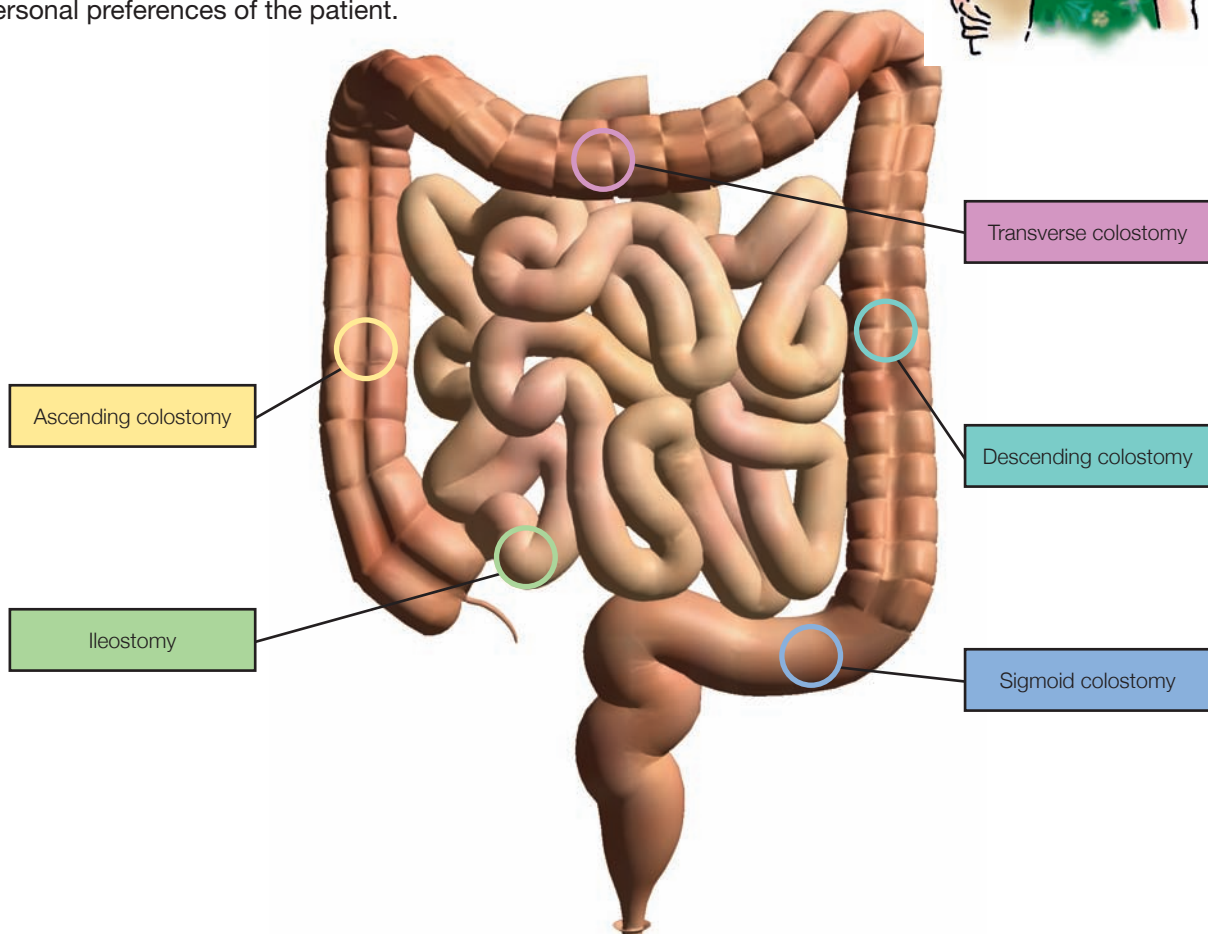
Mr. Z, a 27-year-old White American, is a psychologist with a history of ulcerative

Colostomy and ileostomy care

A patient with a colostomy or ileostomy wears an external pouch over the ostomy site, attached via a hydrocolloid wafer. The pouch collects fecal matter, helps control odor, and protects the stoma and peristomal skin. Most disposable pouching systems can be used for 7 days, unless a leak develops.

When selecting a pouching system, choose one that delivers the best adhesive seal and skin protection for that patient. Other considerations include the stoma's location and structure, consistency of the fecal matter, availability and cost of supplies, amount of time the patient will wear the pouch, any known adhesive allergy, and the personal preferences of the patient.

The best time to change a pouching system is first thing in the morning or 2 to 4 hours after meals, when the bowel is least active. After a few months, most patients can predict the time that's best for them.



colitis since age 18. His twin sister died from toxic megacolon at age 23. His father died from massive gastrointestinal hemorrhage when the patient was age 7, and his mother died 2 years ago from complications of diabetes. Mr. Z has no other living relatives, but he does have several friends who are willing and able to be involved in his care. He's admitted to the surgical floor for the initial stage of a restorative proctocolectomy, also known as an ileal pouch-anal anastomosis.

During admission, the nurse inquires about the prescribed pre-op bowel cleansing and antibiotic regimen. Mr. Z says he drank



1 gallon of polyethylene glycol yesterday as prescribed and is certain his bowel is thoroughly cleansed. He also tells the nurse he

took antibiotics as prescribed and has been N.P.O. since 10 p.m.

Then he explains that the surgeon has told him during this first surgical procedure, his colon and rectum will be removed, but his anus and anal sphincter muscles will be preserved. The surgeon will create a pouch from the ileum and connect it to the patient's anus. Mr. Z will have a temporary ileostomy to allow time for this pouch to heal. The temporary ileostomy is an opening to the skin surface that allows collection of fecal matter in a pouch or ostomy appliance. He expects to have this temporary ileostomy for 8 to 12 weeks.

Mr. Z has explored various ileostomy pouching systems on the Internet and has brought the type he wants to use to the hospital. He says his surgeon agreed to use this type of system as long as the packaging is sterile. Mr. Z presents the nurse with an unopened box of a well-

known brand of two-piece drainable appliances. Across the package are the words "sterile until opened."

Later that day, Mr. Z has the first surgery performed laparoscopically. He's kept in the CCU for 48 hours, and transferred to the medical-surgical unit on the third post-op day. During her initial assessment after Mr. Z's transfer, the nurse finds his abdomen soft and nontender, with an ileostomy on the lower right side. The stoma is red, and about 100 mL of cloudy

Definitions

- **Ostomy:** a surgical procedure used to create an opening for urine and feces to be released from the body
- **Colostomy:** a surgical procedure where a portion of the large intestine is brought through the abdominal wall to carry stool out of the body
- **Anal anastomosis:** a surgery that involves attaching the ileum to the anus after the entire colon and rectum have been removed, allowing the patient to pass stool normally and avoid colostomy
- **Ileostomy:** the surgical creation of an opening into the ileum, with a stoma on the abdominal wall
- **Ileal conduit:** the surgical anastomosis of the ureters to one end of a detached segment of ileum, the other end being used to form a stoma on the abdominal wall
- **Urostomy:** the surgical construction of an artificial excretory opening from the urinary tract; a diversion of the urinary flow away from the bladder, resulting in output through the abdominal wall; the most common method involves using a portion of intestine to conduct the urine out through the abdomen and into an external pouch worn for urine collection
- **Stoma:** a surgically constructed opening, especially one made in the abdominal wall to permit the passage of waste
- **Ileal pouch:** a surgically created chamber made up of a portion of the lower part of the ileum, the last (lowest) part of the small intestine
- **Skin barrier or wafer:** a pectin-based wafer used to protect the skin from irritating drainage

cheat

sheet

serosanguineous effluent is near the tail closure.

Mr. Z has a nasogastric tube and a urinary catheter in place, and both are functioning. For pain management, Mr. Z has patient-controlled analgesia, which he uses infrequently. When asked about his pain, he says it's less severe than one of his ulcerative colitis attacks, rating it a 3 out of 10 on a 0-to-10 pain rating scale. He's looking forward to a rapid recovery and hospital discharge.

The following day, active bowel sounds are auscultated, and both the nasogastric tube and urinary catheter are removed. His post-op recovery continues, and he begins to empty his ileostomy appliance while the nurse is at the bedside. During the rest of his hospital stay, the nurse provides education about completely changing the ileostomy appliance every 4 to 6 days and as necessary if leaking occurs. The nurse explains that the effluent is acidic and will cause a chemical burn due to digestive enzymes if it's allowed to remain on the skin. Mr. Z has a high-output ileostomy, with a daily output of 2 L/day, so emptying the appliance up to 8 to 10 times/day is critical to keeping his peristomal skin intact.

Before discharge, Mr. Z can change his ileostomy pouch and explain his diet, medications, and where he'll obtain additional ostomy supplies. Important education includes drinking enough fluid daily to replace ileostomy losses, chewing all food thoroughly, and eating foods that thicken the effluent such as pasta or potatoes without fat-filled sauces. He may also discuss with his healthcare provider the use of medications to thicken the effluent.

On the eighth post-op day, Mr. Z is discharged home and will be followed by the home health WOC nurse. He's accompanied by two close friends who've also been taught (with the patient's permission) how to manage his ileostomy, diet, and activities. They plan on remaining with him at his home until he's independent in his care.

Caring for a patient with a urostomy

Mr. S, a 55-year-old Hispanic American, is a computer programmer with three adult children. He had an ileal conduit for bladder cancer 4 days ago. An ileal conduit is the most common surgical procedure for invasive bladder cancer.

During the nurse's initial assessment, the urostomy pouch, located to the right of the umbilicus, drains cloudy yellow urine with mucus strings into a bedside drainage bag. The nurse notes the presence of ureteral stents in the stoma.

Mr. S's abdomen is soft and tender to palpation, with active bowel sounds. The stoma is dark red, about 1 in (2.5 cm) above the skin. The color, location, and size of this stoma are considered normal. The patient asks the nurse to help him to the bathroom. He disconnects the bedside drainage bag tubing and closes the valve at the end of the urostomy pouch, placing a cap over the bedside drainage tubing. In the bathroom, he places the end of the pouch between his legs and allows it to completely drain into the toilet before closing the valve once again.

Later that day, the nurse helps Mr. S change his appliance in the bathroom using a one-piece urostomy appliance with a skin barrier constructed for use with urine. (For how to change a two-piece pouching system, see *Applying a skin barrier and pouch*.) Although his hands shake because he's nervous, he traces a pattern onto the back of the new skin barrier and cuts the opening $\frac{1}{16}$ -in larger than his stoma. With the nurse's assistance, he removes the old appliance, using a push-pull technique to reduce skin trauma. Mr. S uses a clean facecloth moistened with water to clean the peristomal skin. Then he places a roll of gauze at the opening of the stoma to collect the continuous urine flow while he pats the skin dry with tissue. He quickly removes the rolled gauze and secures the new appliance, looking in the mirror for correct placement and smoothing the skin barrier in place.

Urostomy is used to divert urine.

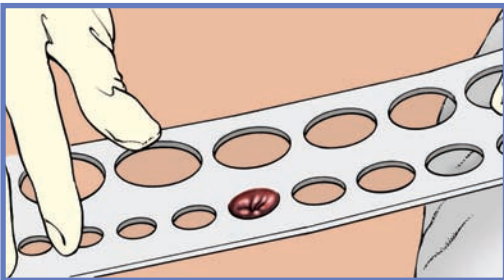


Applying a skin barrier and pouch

Fitting a skin barrier and ostomy pouch properly can be done in a few steps. Shown here is a two-piece pouching system with flanges, which is commonly used.

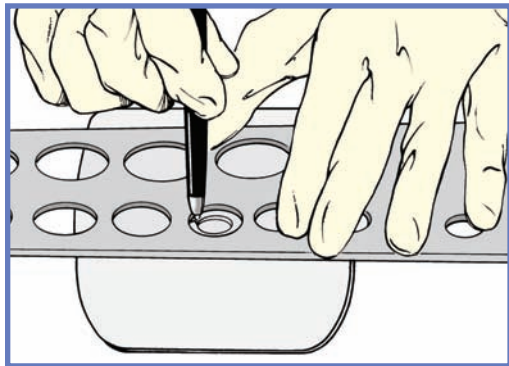
1

Measure the stoma using a measuring guide.



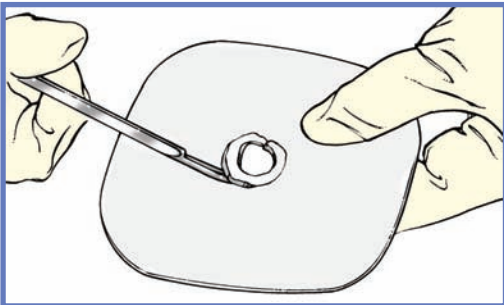
2

Trace the appropriate circle carefully on the back of the skin barrier.



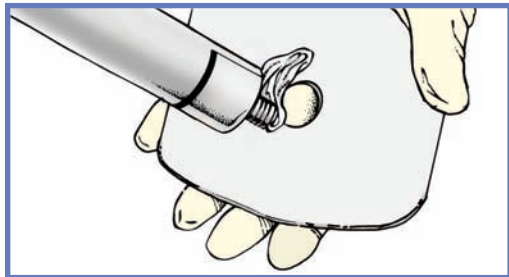
3

Cut the circular opening in the skin barrier. Bevel the edges to keep them from irritating the patient.



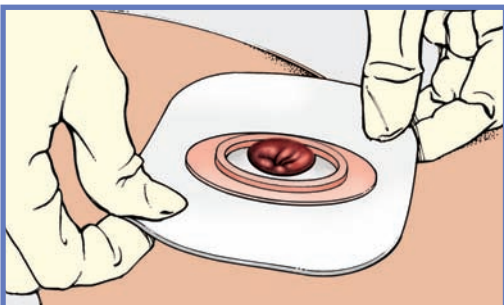4

Remove the backing from the skin barrier and moisten it or apply barrier paste, as needed, along the edge of the circular opening.



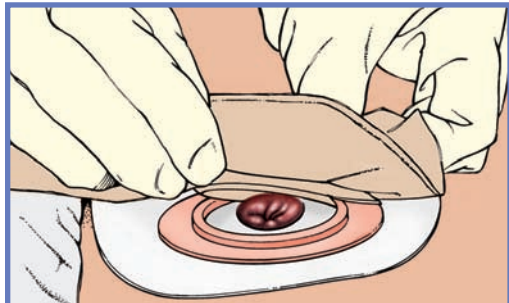
5

Center the skin barrier over the stoma, adhesive side down, and gently press it to the skin.



6

Gently press the pouch opening onto the ring until it snaps into place.



Safely back in bed, Mr. S asks about a special diet. For a patient with a urostomy, drinking at least eight 8-oz glasses of water/day is most important, and drinking cranberry juice will help keep his urine acidic. Although he can eat garlic, asparagus, and onions, they'll give his urine a strong odor. The nurse reassures him that the material of his pouch will generally contain any odor until he empties the urine.

During this discussion, Mr. S also asks about limitations to his physical activity. He can gradually resume activity like any post-op patient who's had abdominal surgery, but he shouldn't engage in contact sports that may involve a direct blow to his abdomen. He should avoid heavy lifting until his surgeon gives approval.

The nurse's role

Unless the patient needed an emergency surgical procedure, the ostomy is likely to have been preceded by some or many procedures. The testing and diagnosis may have created confusion and anxiety for many patients and their families or caregivers.

Some healthcare organizations employ WOC nurses, who may have preoperatively marked the preferred site for the stoma and provided patient and family education throughout the patient stay. Although these same WOC nurses may follow the patient with an ostomy from pre-op care to home health, the nurse who's responsible for caring for a patient with an ostomy is also responsible for providing patient education.

Whether the direct care nurse provides ostomy care and education depends on the facility and geographic location of the healthcare organization. In some facilities, and in some parts of the country, the WOC nurse is a consultant who's responsible for working directly with patients during the pre-op phase of care for stomal marking and education. In such situations, the WOC nurse may provide direct post-op care to all

patients, or only to those with a complicated post-op course requiring the WOC nurse's expertise.

Prepared to care

The three examples presented here represent the more common ostomies encountered in the United States. By being prepared to care for and teach patients like these, you can help them more easily adjust to the new realities of daily life. ■

Learn more about it

American Cancer Society. Colostomy: a guide. <http://www.cancer.org/treatment/treatmentsandsideeffects/physicalsideeffects/ostomies/colostomyguide/colostomy-intro>.

American Cancer Society. Ileostomy: a guide. <http://www.cancer.org/treatment/treatmentsandsideeffects/physicalsideeffects/ostomies/ileostomyguide/ileostomy-intro>.

American Cancer Society. Urostomy: a guide. <http://www.cancer.org/treatment/treatmentsandsideeffects/physicalsideeffects/ostomies/urostomyguide/urostomy-intro>.

American College of Surgeons. Ostomy home skills program. <http://www.facs.org/patienteducation/skills/ostomy.html>.

Beck DE, Roberts PL, Saclarides TJ, Senagore AJ, Stamos MJ, Wexner SD. *The ASCRS Textbook of Colon and Rectal Surgery*. 2nd ed. New York, NY: Springer Science&Business Media; 2011.

Brewer MB. Ileal pouch-anal anastomosis. <http://emedicine.medscape.com/article/1892231-overview>.

Cancer Research UK. Types of surgery for invasive bladder cancer. <http://www.cancerresearchuk.org/cancer-help/type/bladder-cancer/treatment/invasive/surgery/types-of-surgery-for-invasive-bladder-cancer>.

Cappell MS. Pathophysiology, clinical presentation, and management of colon cancer. *Gastroenterol Clin North Am*. 2008;37(1):1-24.

Carlsson E, Gylin M, Nilsson L, Svensson K, Alverslid I, Persson E. Positive and negative aspects of colostomy irrigation: a patient and WOC nurse perspective. *J Wound Ostomy Continence Nurs*. 2010;37(5):511-516.

Cima RR, Pemberton JH. Ileostomy, colostomy, and pouches. In: Feldman M, Friedman LS, Brandt LJ, eds. *Sleisenger and Fordtran's Gastrointestinal and Liver Disease: Pathophysiology/Diagnosis/Management*. 9th ed. Philadelphia, PA: Saunders Elsevier; 2010.

Deitz D, Gates J. Basic ostomy management, part 1. *Nursing*. 2010;40(2):61-62.

Deitz D, Gates J. Basic ostomy management, part 2. *Nursing*. 2010;40(5):62-63.

MedlinePlus. Total proctocolectomy and ileal-anal pouch. <http://www.nlm.nih.gov/medlineplus/ency/article/007380.htm>.

Moore AK, Esquibel KA, Thal W. Ostomy options for clients with ileostomies. *Gastroenterol Nurs*. 2008;31(6):418-420.

Work with your facility's WOC nurse to ensure proper patient education.



National Cancer Institute. Colon cancer treatment. <http://www.cancer.gov/cancertopics/pdq/treatment/colon/HealthProfessional/page10>.

National Comprehensive Cancer Network. NCCN clinical practice guidelines in oncology. http://www.nccn.org/professionals/physician_gls/f_guidelines.asp.

Ostomy Guidelines Task Force, Goldberg M, Aukett LK, et al. Management of the patient with a fecal ostomy: best practice guideline for clinicians. *J Wound Ostomy Continence Nurs*. 2010;37(6):596-598.

Turnbull GB. Managing oversight of colostomy irrigation in long term-care. *Ostomy Wound Manage*. 2003;49(10):13-14.

Wound Ostomy and Continence Nurses Society. Basic ostomy skin care: a guide for patients and health care providers. http://www.ostomy.org/ostomy_info/wocn/wocn_basic_ostomy_skin_care.pdf.

The author has disclosed that she's a speaker for ConvaTec.

The author and planners have disclosed that they have no financial relationships related to this article.

DOI-10.1097/01.NME.0000432867.93012.55

Want more
CE? You
got it!



For more than 99 additional continuing education articles related to skin and wound care control topics, go to Nursingcenter.com/CE.

CE CONNECTION

Earn CE credit online:

Go to <http://www.nursingcenter.com/CE/nmie> and receive a certificate *within minutes*.

INSTRUCTIONS

The ins and outs of ostomy management

TEST INSTRUCTIONS

- To take the test online, go to our secure Web site at <http://www.nursingcenter.com/CE/nmie>.
- On the print form, record your answers in the test answer section of the CE enrollment form on page 56. Each question has only one correct answer. You may make copies of these forms.
- Complete the registration information and course evaluation. Mail the completed form and registration fee of \$21.95 to: Lippincott Williams & Wilkins, CE Group, 74 Brick Blvd., Bldg. 4, Suite 206, Brick, NJ 08723. We will mail your certificate in 4 to 6 weeks. For faster service, include a fax number and we will fax your certificate within 2 business days of receiving your enrollment form.
- You will receive your CE certificate of earned contact hours and an answer key to review your results. There is no minimum passing grade.
- Registration deadline is October 31, 2015.

DISCOUNTS and CUSTOMER SERVICE

- Send two or more tests in any nursing journal published by Lippincott Williams & Wilkins together by mail and deduct \$0.95 from the price of each test.
- We also offer CE accounts for hospitals and other health care facilities on nursingcenter.com. Call 1-800-787-8985 for details.

PROVIDER ACCREDITATION

Lippincott Williams & Wilkins, publisher of *Nursing made Incredibly Easy!*, will award 2.3 contact hours for this continuing nursing education activity.

Lippincott Williams & Wilkins is accredited as a provider of continuing nursing education by the American Nurses Credentialing Center's Commission on Accreditation.

This activity is also provider approved by the California Board of Registered Nursing, Provider Number CEP 11749 for 2.3 contact hours. Lippincott Williams & Wilkins is also an approved provider of continuing nursing education by the District of Columbia and Florida #FBN2454.

Your certificate is valid in all states.

The ANCC's accreditation status of Lippincott Williams & Wilkins Department of Continuing Education refers only to its continuing nursing educational activities and does not imply Commission on Accreditation approval or endorsement of any commercial product.