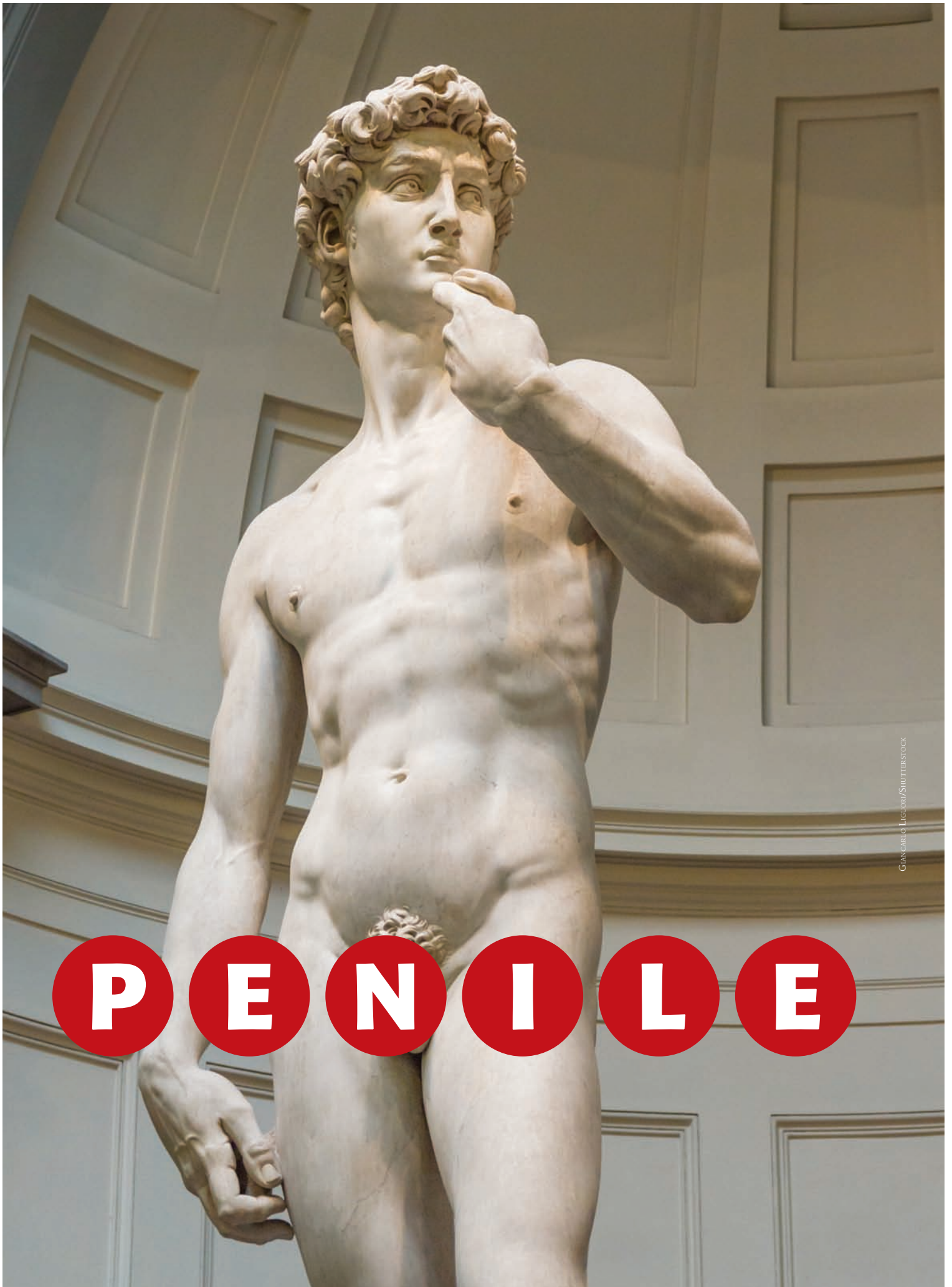

GIANCARLO LIGUORI/SHUTTERSTOCK

A RARE DISEASE, cancer of the penis accounts for less than 1% of all malignancies in the United States and the Western World. About 80% of cases are diagnosed in men over age 55.<sup>1-3</sup> Because of its rarity, most nurses and other healthcare professionals have never cared for a patient with cancer of the penis.

When diagnosed with penile cancer, a man is likely to experience fear about his mortality, sexual function, and masculine identity.<sup>4,5</sup> This article will help the nurse understand the pathophysiology of cancer of the penis, treatment approaches, patient teaching, and psychosocial support. See *Reviewing penile anatomy and physiology* for background on normal penile function and structure.

### **Squamous cell carcinoma**

Cancer of the penis, which most often begins in flat skin cells called squamous cells, can occur anywhere on the penis. Squamous cell carcinoma (SCC) accounts for approximately 95% of penile cancers.<sup>6</sup>

SCCs are most often associated with penile intraepithelial neoplasia (PeIN), a dysplastic process involving a new tumor. Human papillomavirus (HPV) infection, preexisting dermatoses, and lack of circumcision are among the risk factors that trigger development of PeIN.<sup>7-9</sup> (See *Risk factors for penile SCC*.)

PeIN is diagnosed through a biopsy of the penile lesion. Histologically, PeIN lesions present with many variants, but most often have a wart-like, spiky, and/or a basaloid appearance, meaning that tissues look abnormal at the lowest level of the epidermis. PeIN is graded according to significance or severity. For example, Grade 1 is mild, Grade 2 is moderate, and Grade 3 is severe and termed *high-grade PeIN* or *SCC in situ*.<sup>7</sup> This is considered by most researchers to be the earliest form of SCC.<sup>6,7</sup>

SCC in situ is confined to the epidermis and doesn't involve lymph nodes or other body organs.<sup>6,9</sup> Lesions are further classified by the pathologist into differentiated and

# C A N C E R

## Providing patient support

By Richard L. Pullen, Jr., EdD, MSN, RN, CMSRN

undifferentiated cells. *Differentiated cells* may look virtually normal with some immature cells that suggest early-stage malignancy. *Undifferentiated cells*, which are immature and lack normal tissue structure, are associated with advanced malignancy. Most PeIN lesions are differentiated.<sup>6,9</sup>

In SCC in situ of the penis, lesions may gradually undergo cell mutation, become malignant, invade surrounding tissues and internal

structures of the penis, and enter the bloodstream and lymphatic system.<sup>6,7</sup> Lymph nodes in the groin are usually the initial site to which the malignancy spreads, followed by a larger metastatic process involving intrapelvic lymph nodes. Metastases may also be found in the lungs, liver, bone, brain, and skin.<sup>9</sup>

A very rare type of SCC of the penis that isn't associated with PeIN is verrucous carcinoma, sometimes referred

to as Buschke-Lowenstein tumor. This lesion looks like a large genital wart and can grow deep into penile tissues and structures, causing significant destruction. However, regional lymph node involvement and distant metastasis don't usually occur.<sup>1,10,11</sup>

### Non-SCC cancers

About 5% of penile cancers are non-SCC.<sup>10</sup> Changes in melanocytes on the penis can lead to **melanoma**, most often on the glans, followed by the foreskin and then the shaft and urethral meatus.<sup>1,6,10,11</sup> These lesions are more common in older men than in younger men and have a high probability of metastasis if not treated early.

**Sarcoma** is a soft tissue malignancy that arises from changes in the cells of blood vessels, smooth muscles, and connective tissues. These lesions may metastasize.<sup>1,6,10,11</sup>

Changes in basal cells of the epidermis may lead to **basal cell carcinoma** of the penis, which has a low probability of metastasis.<sup>1,6,10,11</sup>

The pathologist will use the Tumor, Node, and Metastasis (TNM) Classification System to stage SCC and non-SCC penile lesions. This system stages or grades tumor size and characteristics, involvement of lymph nodes, and presence of metastasis. See *Staging penile cancer* for an abbreviated version of this system.<sup>12,13</sup>

### Signs and symptoms of SCC

The three types of SCC in situ are Erythroplasia of Queyrat (EQ), Bowen disease (BD), and Bowenoid papulosis (BP).<sup>1,14,15</sup> EQ, BD, and BP have the same histologic features although they differ in location on the penis: EQ lesions are located on the glans and foreskin and BD and BP lesions are located on the shaft. Lesions aren't usually painful, although they may be slightly uncomfortable in the early stages.<sup>7</sup>

Because lesions may be very small, painless, and obscure, patients may not be alarmed and delay seeking

## Reviewing penile anatomy and physiology<sup>1,38,39</sup>

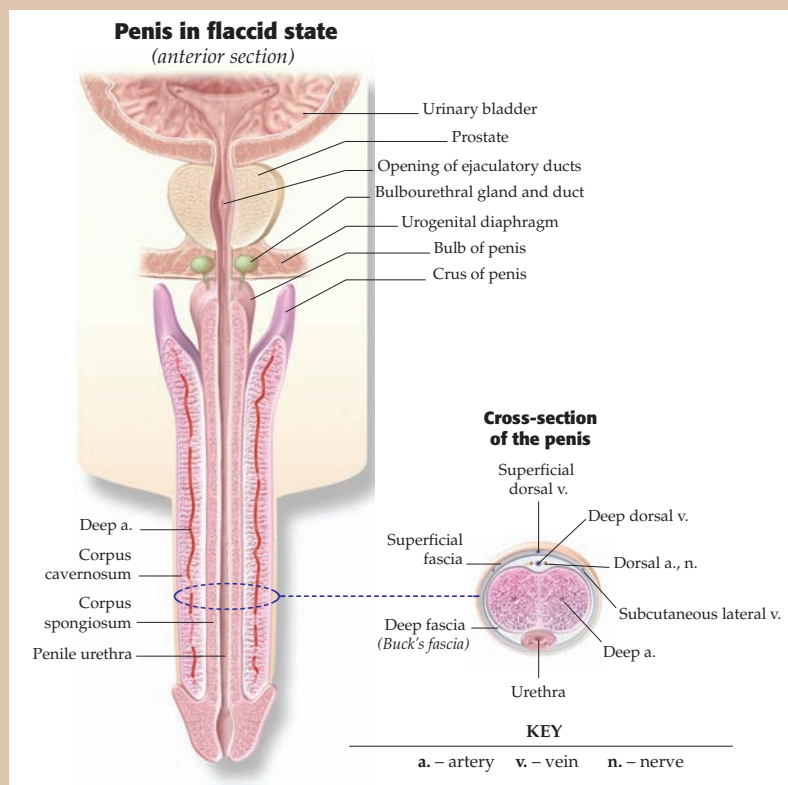
The penis has three main functions:

- to serve as a passageway for urine from the bladder through the urethra
- to serve as a passageway for sperm for reproduction
- to provide sexual pleasure.

The top of the penis, called the glans, is the location of many sensitive nerves and the meatus from which urine flows via the urethra. A foreskin (prepuce) covers the glans in uncircumcised men.

The body or shaft of the penis contains two corpora cavernosa and one corpus spongiosum. These columns of tissue fill with blood to make erection possible.

Blood supply comes from the dorsal arteries of the penis, deep arteries of the penis, and bulbourethral artery, which are divisions of the internal pudendal artery and internal iliac artery. Nerves, muscles, ligaments, and lymphatics also help ensure proper functioning of the penis.



Source: Anatomical Chart Company

## Risk factors for penile SCC

Approximately 80% of SCC in situ cases are related to HPV infection, especially HPV type 16 and HPV type 18, which carry a high risk for penile and cervical cancer. HPV type 16 and HPV type 18 are mainly transmitted through sexual activity.<sup>17,35,36</sup> Other risk factors include the following:<sup>17,37</sup>

- lack of circumcision. Uncircumcised men are at an increased risk because the foreskin covers the glans where smegma, a sebaceous secretion, can accumulate and become a source of irritation to sensitive tissue. The foreskin may become taut in some men as they age, making it difficult to retract and trapping smegma. This condition is called phimosis.
- chronic irritation by urine, friction, and poor hygiene of the penis.
- cigarette smoking. Nicotine is a known carcinogen.
- exposure to UV light, especially when the genitals are exposed, can damage skin cells due to chronic inflammation.
- immunosuppression from disease processes and/or medications, which exposes the patient to opportunistic infections, including HPV and HIV.
- medical conditions of the penis such as genital warts, urinary tract infection, penile tears among men who were never circumcised, chronic penile rash lasting 1 month or longer, penile injury, and urethral stricture.

treatment. When a man does seek treatment, lesions may be misdiagnosed as genital lichen sclerosus, a chronic inflammatory dermatosis of unknown origin, dermatitis, psoriasis, or condyloma (warts).<sup>2,7,10,16</sup>

EQ may initially manifest as an erythematous rash or irritation on the glans that's persistent and unresponsive to topical medications. Lesions are well defined and may be smooth, red, and velvety. (See *Erythroplasia of Queyrat*.) Some lesions may have a red to white appearance and may be pruritic. Over time, lesions may bleed and become crusty, scaly, ulcerated, and painful. An uncircumcised patient may have trouble retracting the foreskin. EQ becomes invasive SCC in 10% to 30% of cases.<sup>1,7,11</sup>

BD lesions are usually single, scaly, dull red plaques that may have areas of crusting. (See *Bowen disease*.) Lesions may be heavily pigmented and resemble melanoma. The differential diagnosis in BD includes BP, psoriasis, and superficial basal cell carcinoma. Invasive SCC occurs in 5% of BD cases.<sup>1,7</sup>

More common in younger men, BP lesions are typically multiple, slightly elevated, and red or violet in color. Although usually benign, BP

can progress to invasive SCC. Infection with HPV 16 has been implicated in the development of BP.<sup>1,2,17,18</sup>

Signs and symptoms of BP and BD differ only slightly. BP may present with multiple lesions that look like small genital warts, whereas BD lesions are usually single and very isolated. BP is generally considered a benign dermatosis and may resolve spontaneously or progress to BD.

Both BP and BD are linked to HPV infection. Another distinction between BD and BP is that BP occurs more often in sexually active young

men and in women who are exposed to HPV.<sup>1,2,7,10,14,17</sup>

Difficulty with urination and achieving an erection are common symptoms when noninvasive disease becomes a metastatic process because of tumor burden on the urethra, corpora cavernosa, and corpus spongiosum.<sup>17,19</sup>

## Signs and symptoms of non-SCC cancer

Melanoma usually develops on areas of the body frequently exposed to the sun. When it develops on the penis, tumor thickness may be greater than it would be on other areas of the body. Like melanoma lesions found on other areas of the body, penile lesions can be brown, blue, black, raised, or flat, with asymmetrical borders. Subtle, asymmetrical changes in pigmentation on the penis should raise a red flag and be evaluated further.<sup>1,6,10,11</sup>

Sarcomas may present with a non-painful lump anywhere on the penis. Basal cell carcinomas are usually raised and nodular, with a low probability of metastasis.<sup>1,6,10,11</sup>

## Health history and physical assessment

When assessing a patient with a penile lesion, develop a trusting rapport during the health history

## Staging penile cancer<sup>12,13</sup>

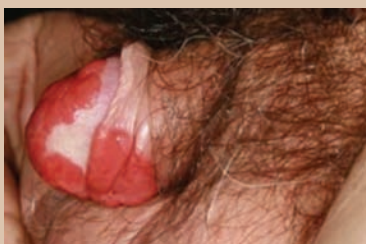Stage	Description
0	Malignancy is confined to the epidermis and is called carcinoma in situ.
1	Malignancy has grown into the tissues below the epidermis of the penis, but hasn't spread to the lymph nodes.
2	Malignancy has grown into the corpus spongiosum or corpus cavernosa or urethra, but hasn't spread to the lymph nodes or other body organs.
3A	Malignancy has grown into the corpus spongiosum or corpus cavernosa or urethra, and has spread to one inguinal lymph node, but hasn't spread to other parts of the body.
3B	Malignancy has grown into the corpus spongiosum or corpus cavernosa or urethra, and has spread to several inguinal lymph nodes, but hasn't spread to other parts of the body.
4	Malignancy has grown into the corpus spongiosum or corpus cavernosa or urethra, and has spread to lymph nodes and other body parts.



interview and head-to-toe assessment. Be aware that he's likely to be anxious and/or depressed.

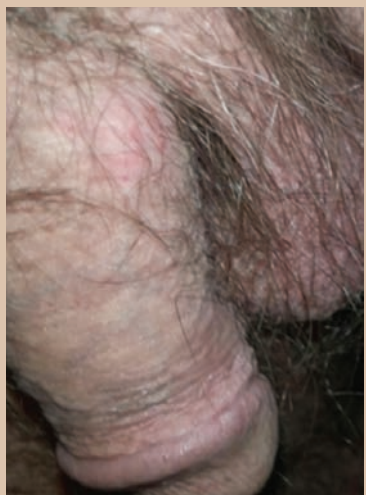Include a social and sexual history in the interview. Some nurses are uncomfortable talking about issues related to sex. Approach this topic from a nonjudgmental perspective, with an understanding that people are sexual beings. To show compassion and offer reassurance, the nurse could say, "I imagine that the lesion on your penis has been frightening to you. I'm glad you're here to take care of it."

### Erythroplasia of Queyrat



Erythroplasia of Queyrat (EQ) is SCC in situ of the glans.

### Bowen disease (BD)



This example of Bowen disease (BD) shows SCC in situ on the lower left shaft. The lesion is subtle, discrete, dull-red, and slightly raised.

Questions that the nurse should ask during the health history interview include:

- When did you first notice the lesion on your penis?
- Is the lesion painful, itchy, or uncomfortable?
- Are you experiencing any other signs and symptoms; for example, are you having any difficulty urinating or achieving an erection?
- Does the lesion look the same all the time or does it change in size, shape, and color; for example, when you take a shower?
- How is your general health, appetite, and energy level?
- What medications are you taking?
- Do you smoke?
- Do you ever tan nude without covering your genitals?
- Are you now or have you ever been sexually active with men, women, or both?
- Have you and your partner or spouse talked about the lesion?
- Have you shared with your partner or spouse how concerning this is to you?

During the physical assessment, carefully inspect any lesions on the penis and surrounding tissues, and palpate the inguinal lymph nodes. Lab studies, including complete blood cell count, should also be performed to assess for systemic disease processes, infections, or inflammation.<sup>4,10,17,19</sup> Additional data used to make a diagnosis include the pathology reports from a biopsy of penile lesions and lymph nodes, and imaging studies such as ultrasound, magnetic resonance imaging, and computed tomography.<sup>14,17</sup>

A histologic evaluation of the lesion and surrounding tissue should be performed as soon as possible from a biopsy specimen. Treatment approaches will depend on the location of the lesion on the penis and whether the carcinoma is invasive or noninvasive.<sup>1</sup>

### Treatment options

The primary goal in managing cancer of the penis is to eliminate the malignancy while preserving a penis that is both functional and cosmetically acceptable to the patient. Excision of noninvasive lesions is recommended for lesions on the glans or shaft. This includes circumcision on the glans.

Removal of noninvasive lesions may require Mohs micrographic surgery.<sup>20</sup> In this procedure, the surgeon slowly removes a layer of skin where the tumor is located. The tissue is examined under a microscope. The procedure is repeated until the skin samples are free from malignancy. The goal is to preserve as much uninvolved penile tissue as possible.<sup>1,21-23</sup>

Lesions may be treated with topical chemotherapy agents such as fluorouracil 5% cream that break down malignant cells while preserving normal skin. Some lesions may also be treated with cryotherapy, which causes cellular membrane dysregulation and cell death. Commonly used to treat genital warts and premalignant lesions of the penis, cryotherapy tends to cause blistering and is sometimes painful.<sup>17,19</sup> Laser ablation is also an option for early-stage penile cancers.<sup>20</sup>

Patients with metastasis may require systemic chemotherapy for disease control and symptom management and to reduce disease activity so that the patient will benefit from lymph node dissection. Commonly used agents are methotrexate and cisplatin.<sup>20</sup> Patients must be monitored for infection because the immune system is profoundly depressed during therapy. The nurse should monitor the patient's absolute neutrophil count to assess the degree of immunosuppression during therapy.

Systemic chemotherapy is often administered in combination with other therapies such as radiation.<sup>24</sup> Radiation therapy may affect a man's ability to have an erection, damage surrounding tissue, and cause painful urethral strictures.<sup>25-27</sup>


Penile cancers have a proclivity for metastasizing to the inguinal lymph nodes. Lymph node involvement is the single greatest prognostic indicator of patient survival. The research evidence suggests that a radical lymphadenectomy (dissection) can arrest malignancy in patients with penile cancer who are at a high risk for metastasis.

Metastasis follows a predictable pattern from the primary penile tumor to the inguinal lymph nodes before spreading to the pelvic lymph nodes and then disseminating to the rest of the body. Although the surgical procedure is known to be curative in about 50% of patients, the potential for postoperative complications is considerable; these include wound infection, venous thromboembolism, and lymphedema, especially when the patient has comorbidities.<sup>28-30</sup>

### Penile preservation techniques

*Total glans resurfacing* involves a dissection of epithelial layers of the glans for patients with noninvasive lesions. A partial-thickness graft is obtained from the thigh to replace the excised penile tissue. The procedure has demonstrated acceptable penile function and oncologic outcomes.<sup>21-23</sup>

A *glansectomy* may be performed for patients with some invasive disease. In this procedure, the glans is completely excised to the distal ends of the corpora. A urethral meatus is created using skin from the penile shaft. The patient will have an indwelling urinary catheter after the procedure to protect the urethra from damage. Patients must also rest for several days to allow the skin graft and remaining penile tissue to heal and should avoid sexual activity for 4 to 8 weeks. Oncologic outcomes are positive. The appearance and function of the newly reconstructed glans is usually acceptable to patients.<sup>1,21-23,31</sup>



**Research shows that most men want to keep their diagnosis a secret because they're embarrassed.**

Another penile preservation technique is a *partial penectomy*, or partial removal of the penis. Due to invasive disease, the entire glans and a portion of the shaft are removed. Grafts are used to replace excised tissue. Lymph node dissection may also be necessary. A surgical dressing is placed over the penis and an indwelling urinary catheter will be in place for several days. Patients must be monitored for edema and bleeding. After the urinary catheter is removed, the patient should support the groin during urination to avoid pressure on the surgical site. After partial penectomy, the man should be able to stand to void with a directed stream of urine and have satisfactory sexual function. He should avoid sexual activity for 4 to 8 weeks.<sup>1,21-23,31</sup>

### Total penectomy

Invasive carcinoma of the glans or shaft and even noninvasive forms of

verrucous carcinoma of the glans (because of its destructive nature) may require total or radical penectomy (total amputation of the penis) if the patient's condition can't be managed with more conservative treatments. Lymph node dissection may also be necessary.<sup>20-23</sup>

The surgeon will perform a perineal urethrostomy and redirect the urethra to the area between the scrotum and rectum. After this procedure, the patient must sit to urinate and can't ejaculate.<sup>2,21-23</sup> An indwelling urinary catheter will be in place for several days and the surgical site should be assessed for bleeding. The patient will be placed on stool softeners to prevent straining during bowel movements and stressing the surgical site.<sup>1,21-23,31</sup>

To address the profound changes in function, lifestyle, and body image, a patient undergoing total penectomy requires a multidisciplinary healthcare team comprised of nurses, including wound care specialists, the urologic surgeon, plastic surgeon, social worker, and counselor.<sup>4,5,22,23</sup>

### Psychosocial impact

A diagnosis of cancer of the penis is frightening. Patients will not only be worried about having a malignancy, they'll also be distressed by its effects on sexual intimacy and masculine identity.<sup>4,5,31</sup> Research shows that most men want to keep their diagnosis a secret because they're embarrassed.<sup>5</sup> Men are likely to experience a roller coaster of emotions from shock, denial, anger, and depression.<sup>5</sup> Just the thought of losing the function of the penis is devastating.

Partial or total penectomy may adversely affect the quality of the patient's life, including his sexual functioning, problems with voiding, and the effect on a sexual partner of the absence of the penis or the appearance of residual penile issue.

Research studies indicate that a man's ability to satisfy himself and his partner sexually with the penis are social expectations. Sexual rehabilitation is possible when the man is in a strong, supportive, and reassuring relationship. After total penectomy, a man can learn to experience sexual pleasure with touching or fondling and through manual stimulation of the scrotum, symphysis pubis, anus, and prostate.<sup>4</sup>

Patients are also concerned about the impact of penectomy on non-sexual intimacy and closeness with their partner and how their partner perceives them as a man and person.<sup>4,5,32,33</sup> Even men who still have a fully functioning penis may fear that lesions will return and become invasive.

### Patient education

Although penile cancer is rare, men should be encouraged to perform regular self-exams of the penis. Teach patients to recognize characteristic signs and symptoms of cancer that should be evaluated by a healthcare provider (see *Nursing assessment checklist*). Also educate patients about genital hygiene and other measures they can take to reduce the risk of penile cancer.

For a patient undergoing treatment, education also includes the following:<sup>1,4,8,21-23,31</sup>

- Encourage the patient to get plenty of rest, eat a well-balanced diet, and remain active to maintain an optimal level of health.
- Teach the patient and his partner, if appropriate, about any prescribed medications, including topical medications and systemic chemotherapy if indicated. Because patients receiving systemic chemotherapy are prone to infection, tell the patient to report any illness, including a cold, sore throat, or fever, and to avoid people who are sick.
- If the patient underwent surgical excision of lesions and surrounding tissue, teach him to report unusual swelling, bleeding, problems voiding, or signs of infection at the incision site to the surgeon.
- After excision of lesions, teach the patient to support the scrotum and penis with an athletic supporter or small cloth placed under the scrotum placed in the man's underwear.
- Teach the patient and his partner proper urinary catheter care if he'll be discharged with the catheter in place.
- Encourage the patient to share his concerns and feelings. Open discussion can help him feel less isolated. Encourage the man's partner to share

concerns and feelings as well. Refer them to resources such as support groups, counseling, and psychosexual therapy.

### Prognosis

Men with carcinoma in situ are expected to live a normal life span, contingent on aggressive treatment and no recurrence of lesions. According to the American Cancer Society, men with Stage 1 or Stage 2 penile cancer have a 5-year survival rate of 85% with treatment. Men with Stage 3 or Stage 4 have a 5-year survival rate of 59% with treatment. However, the 5-year survival rate is 11% for men with penile cancer that has metastasized to other organs.<sup>34</sup>

The risk of cancer of the penis is mitigated by good genital hygiene, lifestyle modification, HPV vaccination, and circumcision. Comorbidities such as chronic illness tend to create additional challenges to prevention. Nurses and their healthcare colleagues need to have a strong knowledge base of cancer of the penis to care for and support men with this potentially life-altering condition. ■

### REFERENCES

1. American Cancer Society. Penile cancer. [www.cancer.org/cancer/penile-cancer.html](http://www.cancer.org/cancer/penile-cancer.html).
2. Nam JK, Lee DH, Park SW, et al. Clinicopathologic characteristics and treatment outcomes of penile cancer. *World J Mens Health*. 2017;35(1):28-33.
3. Sharma P, Zargar-Shostari K, Pettaway CA, Schabath MB, Giuliano AR, Spiess PE. Disparities in penile cancer. *Cancer Control*. 2016;23(4):409-414.
4. Sosnowski R, Kulpa M, Kosowicz M, et al. Quality of life in penile carcinoma patients—post-total penectomy. *Cent European J Urol*. 2016;69(2):204-211.
5. Gordon H, LoBiondo-Wood G, Malecha A. Penis cancer: the lived experience. *Cancer Nurs*. 2017;40(2):E30-E38.
6. Erbersdobler A. Pathologic evaluation and reporting of carcinoma of the penis. *Clin Genitourin Cancer*. 2017;15(2):192-195.
7. Zreik A, Ismail M, Nigam R. Penile intraepithelial neoplasia: management and outcomes. *Human Androl*. 2013;3(1):6-9.
8. Johnson C, Obonor N, DeWeese A. Human papillomavirus and cancer in men. *Health Sci J*. 2016;10(6):479.
9. Nicolás-Párraga S, Gandini C, Pimenoff VN, et al. HPV16 variants distribution in invasive cancers of the cervix, vulva, vagina, penis, and anus. *Cancer Med*. 2016;5(10):2909-2919.

### Nursing assessment checklist<sup>1,10,14,31</sup>

When obtaining a health history or performing a physical assessment, check for:

- uncomfortable, irritating, or painful sensations from lesions or thickened skin anywhere on the penis. Patients may report that lesions become irritated during sexual activity. However, many penile lesions are asymptomatic.
- problems urinating or achieving an erection.
- irregular, blue, brown, red, dull-red, or velvety penile lesions, flat or raised. Penile lesions can appear anywhere on the penis, although the glans is the most common location.
- subtle skin changes on the penis. Ask patients if lesions look different at different times. For example, lesions may be more pronounced after showering or sweating. Changes in appearance over time is a strong indicator of serious pathology.
- thickened skin anywhere on the penis. The color of the thickened skin may blend well with the normal penile tissue.
- ulcerations or crusty lesions anywhere on the penis.
- bleeding or foul-smelling discharge from under the foreskin.
- inguinal lymphadenopathy.

10. Minhas S, Manseck A, Watya S, Hegarty PK. Penile cancer—prevention and premalignant conditions. *Urology*. 2010;76(2 suppl 1):S24-S35.
11. Morris BJ, Krieger JN. Penile inflammatory skin disorders and the preventive role of circumcision. *Int J Prev Med*. 2017;8:32.
12. National Cancer Institute. Staging of penile cancer. [www.cancer.gov/types/penile/patient/penile-treatment-pdq#section/\\_24](http://www.cancer.gov/types/penile/patient/penile-treatment-pdq#section/_24).
13. Huether SE, McCance KL. Alterations in the male reproductive system. In: *Understanding Pathophysiology*. 6th ed. St. Louis, MO: Mosby-Elsevier; 2017:854-877.
14. Micall G. Urogenital squamous cell carcinoma. Medscape. 2017. <http://emedicine.medscape.com/article/1102225-overview>.
15. Marchionne E, Perez C, Hui A, Khachemoune A. Penile squamous cell carcinoma: a review of the literature and case report treated with Mohs micrographic surgery. *An Bras Dermatol*. 2017;92(1):95-99.
16. Pappas-Taffer LK. Lichen sclerosis. Medscape. 2017. <https://emedicine.medscape.com/article/1123316-overview>.
17. Fernandez MJ, Sanchez DF, Cubilla AL. Pathology, risk factors, and HPV in penile squamous cell carcinoma. In: Cullin DJ, ed. *Management of Penile Cancer*. New York, N.Y.: Springer; 2014:21-45.
18. Pettaway CA. Carcinoma of the penis: clinical presentation, diagnosis, and stages. UpToDate. 2017. [www.uptodate.com](http://www.uptodate.com).
19. Parker DC. Malignant dermatological diseases of the male genitalia. Medscape. 2017. <http://emedicine.medscape.com/article/454810-overview>.
20. Pettaway CA. Carcinoma of the penis: surgical and medical treatment. UpToDate. 2017. [www.uptodate.com](http://www.uptodate.com).
21. Li P, Song N, Yin C, et al. Glans-preserving surgery for superficial penile cancer. *J Androl*. 2012;33(3):435-440.
22. Burnett AL. Penile preserving and reconstructive surgery in the management of penile cancer. *Nat Rev Urol*. 2016;13(5):249-257.
23. Zukiwskyj M, Daly P, Chung E. Penile cancer and phallus preservation strategies: a review of current literature. *BJU Int*. 2013;112(suppl 2):21-26.
24. Sharma P, Djajadiningrat R, Zargar-Shoshtari K, et al. Adjuvant chemotherapy is associated with improved overall survival in pelvic node-positive penile cancer after lymph node dissection: a multi-institutional study. *Urol Oncol*. 2015;33(11):496.e17-496.e23.
25. American Cancer Society. Radiation therapy for penile cancer. [www.cancer.org/cancer/penile-cancer/treating/radiation-therapy.html](http://www.cancer.org/cancer/penile-cancer/treating/radiation-therapy.html).
26. Van Poppel H, Watkin NA, Osanto S, Moonen L, Horwich A, Kataja V. Penile cancer: ESMO Clinical Practice Guidelines for diagnosis, treatment and follow-up. *Ann Oncol*. 2013;24(suppl 6):vi115-vi124.
27. Crook J. Radiation therapy for cancer of the penis. *Urol Clin North Am*. 2010;37(3):435-443.
28. O'Brien JS, Perera M, Manning T, et al. Penile cancer: contemporary lymph node management. *J Urol*. 2017;197(6):1387-1395.
29. Koifman L, Hampl D, Koifman N, Vides AJ, Ornellas AA. Radical open inguinal lymphadenectomy for penile carcinoma: surgical technique, early complications and late outcomes. *J Urol*. 2013;190(6):2086-2092.
30. Ovejero-Gomez VJ, Martin-Cuesta L, Martinez-Bretones F, et al. Inguinal lymphadenectomy assessment associated with penile carcinoma undergone new strategies for nodal staging. *Case Rep Clin Med*. 2014;3(7):410-415.
31. Turner B, Drudge-Coates L, Henderson S. Penile cancer: diagnosis, clinical features and management. *Nurs Stand*. 2013;27(29):50-57.
32. Branney P, Witty K, Braybrook D, Bullen K, White A, Eardley I. Mortality and sexuality after diagnosis of penile cancer: a participative study. *Int J Urol Nurs*. 2016;10(3):137-145.
33. Sansalone S, Silvani M, Leonardi R, Vespasiani G, Iacovelli V. Sexual outcomes after partial penectomy for penile cancer: results from a multi-institutional study. *Asian J Androl*. 2017;19(1):57-61.
34. American Cancer Society. Penile cancer survival rates. [www.cancer.org/cancer/penile-cancer/detection-diagnosis-staging/survival-rates.html](http://www.cancer.org/cancer/penile-cancer/detection-diagnosis-staging/survival-rates.html).
35. Centers for Disease Control and Prevention. Prevalence of HPV in adults aged 18-69: United States, 2011-2014. [www.cdc.gov/nchs/products/databriefs/db280.htm](http://www.cdc.gov/nchs/products/databriefs/db280.htm).
36. de Martel C, Plummer M, Vignat J, Franceschi S. Worldwide burden of cancer attributable to HPV by site, country and HPV type. *Int J Cancer*. 2017;141(4):664-670.
37. Pettaway CA. Carcinoma of the penis: epidemiology, risk factors, and pathology. UpToDate. 2017. [www.uptodate.com](http://www.uptodate.com).
38. Giuliano F. Neurophysiology of erection and ejaculation. *J Sex Med*. 2011;8(suppl 4):310-315.
39. Huether SE, McCance KL. Male reproductive system. In: *Understanding Pathophysiology*. 6th ed. St. Louis, MO: Mosby-Elsevier; 2017:793-798.

Richard L. Pullen, Jr., is a Professor and Piper Professor of Texas at Texas Tech University Health Sciences Center School of Nursing in Lubbock, Tex.

The author and planners have disclosed no potential conflicts of interest, financial or otherwise.

DOI-10.1097/01.NURSE.0000531005.17471.7d

**For more than 102 additional continuing education articles related to cancer topics, go to [NursingCenter.com/CE](http://NursingCenter.com/CE).**

CE

# CONNECTION

**Earn CE credit online:**  
Go to [www.nursingcenter.com/CE/nursing](http://www.nursingcenter.com/CE/nursing) and receive a certificate within minutes.

INSTRUCTIONS

## Penile cancer: Providing patient support

**TEST INSTRUCTIONS**

- To take the test online, go to our secure website at [www.nursingcenter.com/ce/nursing](http://www.nursingcenter.com/ce/nursing). View instructions for taking the test online there.
- If you prefer to submit your test by mail, record your answers in the test answer section of the CE enrollment form on page 40. You may make copies of the form. Each question has only one correct answer. There is no minimum passing score required.
- Complete the registration information and course evaluation. Mail the completed form and registration fee of \$12.95 to: **Lippincott Professional Development**, 74 Brick Blvd., Bldg. 4, Suite 206, Brick, NJ 08723. We will mail your certificate in 4 to 6 weeks. For faster service, include a fax number and we will fax your certificate within 2 business days of receiving your enrollment form.
- You will receive your CE certificate of earned contact hours and an answer key to review your results.
- Registration deadline is March 6, 2020.

**DISCOUNTS and CUSTOMER SERVICE**

- Send two or more tests in any nursing journal published by Lippincott Williams & Wilkins together by mail, and deduct \$0.95 from the price of each test.
- We also offer CE accounts for hospitals and other healthcare facilities on [nursingcenter.com](http://nursingcenter.com). Call **1-800-787-8985** for details.

**PROVIDER ACCREDITATION**

Lippincott Professional Development will award 1.0 contact hour for this continuing nursing education activity.

Lippincott Professional Development is accredited as a provider of continuing nursing education by the American Nurses Credentialing Center's Commission on Accreditation.

Lippincott Professional Development is also an approved provider of continuing nursing education by the District of Columbia, Georgia, and Florida CE Broker #50-1223. This activity is also provider approved by the California Board of Registered Nursing, Provider Number CEP 11749 for 1.0 contact hour.