

# Posterior Dislocation of the Sternoclavicular Joint

## A Case Study

Marcia Gamez

**T**he posterior dislocation of the sternoclavicular (SC) joint is an uncommon injury and can be easily missed, leading to potentially life-threatening consequences if untreated. An SC joint dislocation accounts for less than 3% of all shoulder injuries, and a posterior dislocation of the SC joint is but a fraction of these injuries (Glass, Thompson, Cole, Gause, & Altman, 2011). In a review of 1,600 SC joint dislocations, only one subject had a posterior dislocation (Cope, 1993). One third of the patients diagnosed with a posterior SC joint dislocation will suffer symptoms related to the compression of the structures that lie posterior to the SC joint (Garg, Alshameeri, & Wallace, 2012). This case study discusses the diagnosis, treatment, and follow-up of a patient with posterior dislocation of the SC joint acquired while playing football.

### History of Present Illness

The patient (A.D.) was a 15-year-old, white male patient who sustained an injury to his right shoulder playing football. He is currently a full-time high school student. After taking a hit to the left side, he fell onto the posterior aspect of his right shoulder producing immediate pain.

Clinic presentation occurred 10 days after the initial injury. The patient's general practitioner saw the patient immediately after the injury; however, chest x-ray findings were read as normal. When the patient continued to complain of pain, shortness of breath, and a pins and needle feeling in his right arm, a computed tomographic (CT) scan of his clavicle without contrast was ordered. A.D. was subsequently referred for further evaluation. Additional complaints identified at the time of referral included difficulty breathing when lying in the supine position or bending forward, and a "pins and needles" feeling in the fingers of his right hand when in these same positions. The patient rates the pain as a 6 or 7 on a scale of 0–10 when the right arm is not immobilized. Pain in the shoulder and chest often awakened the patient from sleep. A.D. also complains of intermittent nausea, loss of appetite, fatigue, and dizziness since the injury occurred. Pain is improved by limiting the range

of motion in the right arm. Sleeping in a chair or upright position allows the patient to sleep without pain and helps prevent perceived dyspnea.

### Physical Examination

A.D. was awake and alert. His parents were in the examination room at the time the history and physical examination were conducted. The patient denied any pain as long as his arm was in a stable position. Shortness of breath was not present unless the patient was lying flat or bending forward. The patient reported fatigue and a loss of appetite since the injury. Overall the patient appeared to be a healthy 15-year-old.

The focused examination of the left shoulder demonstrates 165° of forward elevation, 60°–70° of external rotation, and no pain with active or passive range of motion. The patient had 5/5 strength in the muscles of the rotator cuff.

A.D. showed an abnormality around the right SC joint when compared with the left and was tender to palpation. The patient had forward elevation to 120° with pain. The testing for rotator cuff strength was limited because of pain. Neurovascularly, the patient was intact and had sensation to light touch over his axillary, median, radial, and ulnar distribution. The temperature of the right extremity was equal to the left.

The patient's neck had full range of motion with some discomfort on moving the patient's chin to his chest. There was tenderness noted on palpation on the right side of the anterior aspect of the neck. There was no tenderness on posterior aspect of the neck.

On neurological examination the strength of grips, biceps, and triceps were 5/5 and symmetric. The patient's upper extremities sensation was equal to touch when comparing the right with the left. The deep tendon reflexes were present (++) bilaterally at biceps, triceps, and brachioradialis.

Marcia Gamez, RNFA, CNS, Self-employed RNFA, DNP student, Dallas, TX.

The author and planners have disclosed no potential conflicts of interest, financial or otherwise.

DOI: 10.1097/NOR.000000000000128

A.D. had equal pulses bilaterally at the radial, ulnar, and brachial pulses. The patient's capillary refill was within 1–2 seconds in bilateral upper extremities. The patient's skin temperature was equal bilaterally.

## Radiographs

An anteroposterior radiograph reveals asymmetry of the SC joint on the shoulder girdle view (see Figure 1). The glenohumeral joint is well reduced. The proximal physis is almost closed.

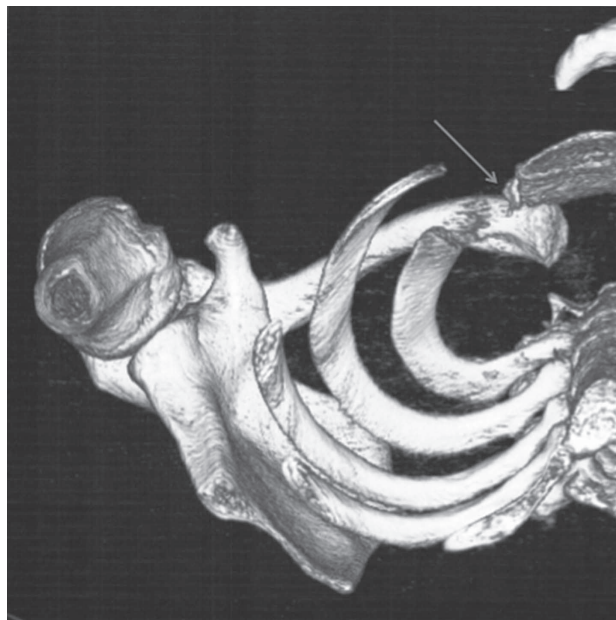
A CT scan with three-dimensional reconstruction shows a posterior dislocation of the right SC joint with a physis injury of the medial clavicle (see Figures 2 and 3). The clavicle is abutting the innominate artery. No evidence of mediastinal hematoma or vascular injury is seen.

## Brief Discussion

A dislocation of the SC joint is not common, accounting for less than 1% of all joint dislocations that occur in the body, with an anterior dislocation occurring 3 times more often than that of a posterior dislocation. This is partially attributed to the strength of the posterior SC ligament (Jaggard, Gupte, Gulati, & Reilly, 2009; Marker & Klareskov, 1996). The usual cause of a posterior dislocation of the SC joint is indirect trauma, with the most common being a direct blow taken to the posterolateral part of the shoulder with the arm adducted and flexed (Cope, 1993; Jaggard et al., 2009; Marker & Klareskov, 1996). Many of these dislocation injuries occur from participating in sports, although they have been seen after motor vehicle accidents or falls from a great height (Garg et al., 2012).

### SIGNS AND SYMPTOMS

The more common symptoms seen with a posterior dislocation of the SC joint are pain around the medial aspect of the clavicle occurring with motion of the shoulder and neck, and a gap or depression felt on examination of the medial aspect of the clavicle along with swelling

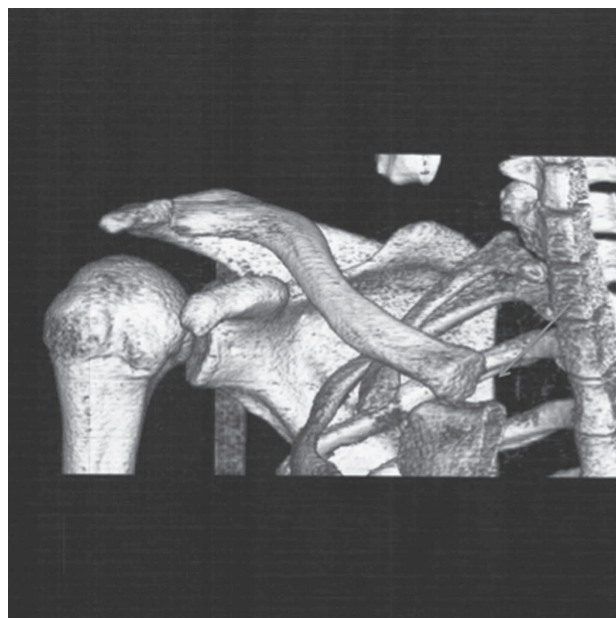


**FIGURE 2.** Computed tomographic 3-dimensional reconstruction of the right SC joint.

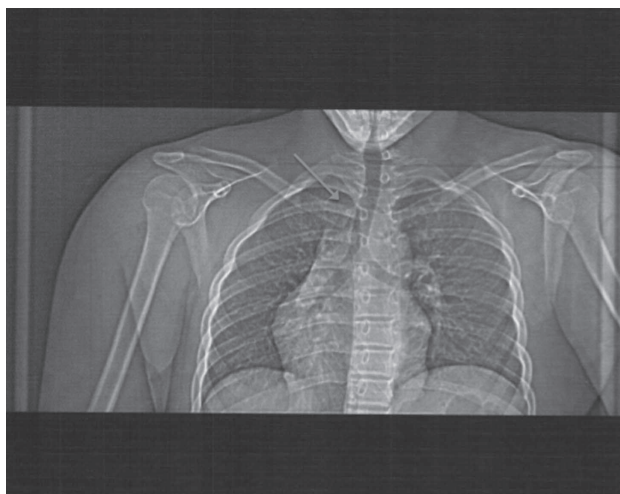
(Cope, 1993; Garg et al., 2012; Jaggard et al., 2009). Other symptoms can include dyspnea, hoarseness, and dysphagia (Cope, 1993; Garg et al., 2012; Jaggard et al., 2009). If the condition goes untreated, more severe symptoms can occur such as tracheal stenosis, cyanosis of the neck and upper extremity, pneumothorax, arterial injury, neurological damage, and thoracic outlet syndrome (Cope, 1993; Garg et al., 2012; Jaggard et al., 2009; Marker & Klareskov, 1996).

### DIAGNOSTIC TESTS

A diagnosis is often made from the history and physical examination (Cope, 1993). Although x-ray films may be taken, a standard chest x-ray film is often inaccurate



**FIGURE 3.** Computed tomographic 3-dimensional reconstruction of the anteroposterior of the chest.



**FIGURE 1.** Anteroposterior x-ray film of the chest.

and hard to interpret. Oblique views such as the Rockford or Serenity view uses a 50° tilt of the x-ray machine with the center on the manubrium. The Hobbs view is performed by a 90° cephalocaudal lateral view of the SC joint. The Heining projection is achieved by having the x-ray beam horizontal to the SC joint and parallel to the opposite clavicle. Any one of the aforementioned views should be ordered if a dislocation is suspected (Cope, 1993; Garg et al., 2012; Jaggard et al., 2009). A CT scan can also be used to help rule out or diagnose damage to the structures that lie posterior to the SC joint (Cope, 1993; Garg et al., 2012; Jaggard et al., 2009; Marker & Klareskov, 1996). If damage to the circulatory system is suspected, then an angiogram or venogram should also be ordered. (Cope, 1993; Garg et al., 2012).

## Treatment

The preferred treatment for a posterior dislocation of the SC joint is a closed reduction (Cope, 1993; Garg et al., 2012; Glass et al., 2011; Marker & Klareskov, 1996). This treatment is most successful if performed within the first 48 hours, but can be used up to 10 days after the initial injury with success (Cope, 1993; Garg et al., 2012; Marker & Klareskov, 1996). A closed reduction is performed under anesthesia and is done by placing a bolster of some type between the scapula of the patient lying in a supine position. Then traction is used on the arm of the affected side, while the arm is in abduction and slowly extended. If a successful relocation is accomplished, it is then recommended that the patient be placed in a figure eight bandage for 6–8 weeks (Garg et al., 2012; Jaggard et al., 2009).

If a closed reduction fails or the physician is unable to reduce the SC joint, then an open reduction internal fixation (ORIF) is recommended and a cardiothoracic surgeon should stand by when the procedure is undertaken (Cope, 1993; Garg et al., 2012; Glass et al., 2010; Jaggard et al., 2009; Marker & Klareskov, 1996). The cardiothoracic surgeon should be on standby in case damage has occurred to the vessels that run posteriorly to the SC joint. There are multiple methods of achieving a stable SC joint through ORIF, and they all have good results with minimal to no complications with one exception, which is the use of pins, rods, or screws to hold fixation (Glass et al., 2010; Jaggard et al., 2009). Some techniques used to reduce the SC joint through an ORIF include the use of a figure eight suture technique, the use of a tendon allograft, resection of the medial clavicle, and metal fixation (Garg et al., 2012; Glass et al., 2010; Jaggard et al., 2009). The use of metal to help sta-

bilize the SC joint has the potential for serious complication due to migration of pins, wires, or screws migrating posteriorly and causing damage to vascular structures. Because of this potential complication, this form of fixation is no longer the standard (Garg et al., 2012; Glass et al., 2010; Jaggard et al., 2009).

## Diagnosis/Initial Plan

After the CT scan was reviewed, the patient was diagnosed as having a posterior dislocation of the SC joint. Open reduction and internal fixation of the right SC joint with suture fixation was the recommended. Because the patient had sustained the injury more than 10 days ago, a closed reduction was not recommended. For a closed reduction to have the best chance for success, it must be performed within 48 hours of the injury, but no later than 10 days postinjury (Jaggard et al., 2009). A cardiothoracic specialist must be available in case of vascular trauma.

## Prognosis

The prognosis for the patient's full recovery, including returning to football, is good. In a study following patients who had a suture fixation repair of a SC posterior dislocation, at 15 months the patients ( $n = 3$ ) had no complaints of pain and full function (Jaggard et al., 2009).

## REFERENCES

- Cope, R. (1993). Dislocations of the sternoclavicular joint. *Skeletal Radiology*, 22, 233–238.
- Garg, S., Alshameeri, Z. A., & Wallace, W. A. (2012). Posterior sternoclavicular joint dislocation in a child: A case report with review of literature. *Journal of Shoulder and Elbow Surgery*, 21, e11–e16. doi: 10.1016/j.jse.2011.07.007
- Glass, E. R., Thompson, J. D., Cole, P. A., Gause, T. M., & Altman, G. T. (2011). Treatment of sternoclavicular joint dislocation: A systematic review of 251 dislocations in 24 case studies. *The Journal of Trauma Injury, Infection, and Critical Care*, 70(5), 1294–1298. doi: 10.1097/TA.0b013e3182092c7b
- Jaggard, M., Gupte, C., Gulati, V., & Reilly, P. (2009). A comprehensive review of trauma and disruption to the sternoclavicular joint with the proposal of a new classification system. *The Journal of Trauma: Injury, Infection, and Critical Care*, 66(2), 576–584. doi: 10.1097/TA.0b013e31817fd96b
- Marker, L. B., & Klareskov, B. (1996). Posterior sternoclavicular dislocation: An American football injury. *British Journal of Sports Medicine*, 30, 72. doi: 10.1136/bjsm.30.1.71

For 6 additional continuing nursing education activities related to sports injuries, go to [nursingcenter.com/ce](http://nursingcenter.com/ce).