

# Plantar Fasciitis

## What Is the Diagnosis and Treatment?

Rachel E. Johnson ▼ Kim Haas ▼ Kyle Lindow ▼ Robert Shields

Foot pain, specifically plantar heel pain, is a common complaint among patients in a podiatric or orthopaedic office setting but may be seen in primary care offices, urgent care centers, or emergency departments as well. There are numerous causes for heel pain, but plantar fasciitis is the most frequent cause. The diagnosis of plantar fasciitis is generally made clinically, but there are many diagnostic modalities that may be used to confirm the diagnosis. Treatment of plantar fasciitis ranges from conservative measures to surgical interventions, but most cases of plantar fasciitis can be managed conservatively. There is no definitive treatment proven to be the best option for plantar fasciitis. Treatment is patient dependent and commonly requires a combination of different modalities to successfully alleviate the symptoms. In this article, plantar fasciitis from defining the disorder, diagnosis, and treatment are discussed.

A patient who all offices and emergency departments may see at some point is one who presents as this case example. A 45-year-old woman comes in to the office with complaints of foot pain that upon questioning is more localized to the right plantar medial surface of the heel. She states that the pain started approximately 3–4 weeks ago without any trauma to the area. She states that the pain is worse in the morning, after periods of rest, and at the end of the day. This patient case begins the typical complaint scenario for the diagnosis of plantar fasciitis. An orthopaedic nurse, whether working in an office, emergency department, or even the orthopaedics floor, will likely see a patient who will present with this chief complaint or follow them possibly in the postoperative area or on the orthopaedic floor. Approximately 10%–16% of the population suffers from plantar fasciitis (Healey & Chen, 2010). Diagnosis and treatment of plantar heel pain account for more than 1 million visits to physicians per year in the United States (Cutts, Obi, Pasapula, & Chan, 2012). Finally, in 80% of patients, symptoms of plantar heel pain are attributed to plantar fasciitis (Neufeld & Cerrato, 2008).

The plantar fascia, or aponeurosis, is a band of connective tissue that supports the arch of the foot (Cutts et al., 2012; Orchard, 2012). The plantar fascia runs predominantly longitudinally and originates from the anterior calcaneal tubercle (Healey & Chen, 2010), more

specifically the medial calcaneal tubercle (Lawrence, Rolen, Morshed, & Moukaddam, 2013), and extends distally into the five metatarsophalangeal joints and ends at the proximal phalanges of the digits (Healey & Chen, 2010; Neufeld & Cerrato, 2008). The fascia has three distinct bands that run along the plantar foot that include the medial, central, and lateral bands. The fibers of the plantar fascia blend into the dermis, flexor tendon sheaths, and the deep transverse metatarsal ligaments among other ligaments (Healey & Chen, 2010). In 1954, Hicks described the plantar fascia to be similar to a Windlass effect or mechanism to the arch (Cutts et al., 2012; Healey & Chen, 2010; Neufeld & Cerrato, 2008). During toe off of gait analysis, the toes are dorsiflexed resulting in a tightening of the plantar fascia along its entire course. This tightening shortens the plantar fascia and increases tension along the fascial band, thus activating the windlass mechanism. This increases the stability and rigidity of the arch and prepares the foot for the propulsive phase of gait (Cutts et al., 2012; Healey & Chen, 2010).

Now that we know what the plantar fascia is and where it is located, the next question is why it becomes painful and debilitating. The term *plantar fasciitis* implies an inflammatory process to the plantar fascia, but literature review may not totally support that implication. Plantar fasciitis is a result from repetitive micro trauma to the fascia (Cutts et al., 2012; Healey & Chen, 2010; Neufeld & Cerrato, 2008). This repetitive micro trauma leads to degeneration and micro tears of the

**Rachel E. Johnson, RN, DPM**, is an Assistant Professor of the Podiatric Medicine Department at Kent State University College of Podiatric Medicine, 6000 Rockside Woods Blvd. Independence, OH 44131. She can be reached at Kent State University College of Podiatric Medicine 216.231.3300 or by email at rjohn112@kent.edu.

**Kimberly Haas, DPM PGY-1**, is currently a first year Podiatric resident at the University Hospital Richmond Medical Center/Kent State University College of Podiatric Medicine.

**Kyle Lindow, MSIII**, is a third year podiatric medical student at Kent State University College of Podiatric Medicine.

**Robert Shields, MSIII**, is a third year podiatric medical student at Kent State University College of Podiatric Medicine.

There were no grant funds with this project.

The authors have disclosed that they have no financial interests to any commercial company related to this educational activity.

DOI: 10.1097/NOR.0000000000000063

plantar fascia, as well as periostitis of the medial calcaneal tubercle (Cutts et al., 2012; Healey & Chen, 2010; Neufeld & Cerrato, 2008). An inflammatory process may result from the micro trauma to the area. Cutts et al., 2012 discuss that few cases of plantar fasciitis lead to surgical intervention and therefore an absence of inflammation in the histology results of these specimens may not be an accurate indication of whether there is a lack of presence of an inflammatory process with plantar fasciitis. Plantar fasciitis is more likely a multifactorial etiology in combination with degeneration and inflammation.

## Risk Factors and Differential Diagnoses

The question may arise: Who is at risk for plantar fasciitis? There are several risk factors associated with plantar fasciitis. Common risk factors include obesity, decreased ankle dorsiflexion or shortened/tight Achilles tendon, runners, pes cavus (high arched foot type), and pes planus (flat foot) (Cutts et al., 2012; Healey & Chen, 2010; Neufeld & Cerrato, 2008). People who stand a large amount of time or work on hard flooring are at higher risk (Healey & Chen, 2010). Recent increase in body weight or recent activity changes may trigger plantar fasciitis symptoms. Patients ranging in age from 40 to 60 years are more frequently diagnosed (Healey & Chen, 2010), but plantar fasciitis is not limited to this range. There may be a higher frequency in women (Orchard, 2012), but the literature is conflicting as to whether there is a gender predilection.

A differential diagnosis list must be considered when a patient presents with foot pain that is localized to the heel. These other diagnoses must be ruled out with a good history, physical examination, and other diagnostic tools if necessary. Differential diagnoses include, but are not limited to, rupture of the plantar fascia, Baxter's neuritis, Tarsal tunnel syndrome, Medial calcaneal nerve entrapment, Fat pad atrophy, Calcaneal stress fracture, bone contusion, infection, neoplasm, plantar fibromatosis, seronegative arthropathies, and rheumatoid arthritis. Many of these differentials may be excluded with an extensive history and physical examination. Below, we will cover the diagnosis and treatment of plantar fasciitis and indicate in some cases where these differentials may be excluded.

## History and Clinical Signs/Symptoms

The diagnosis of plantar fasciitis is made based on clinical history, examination, and with the aid of diagnostic studies when necessary. A thorough history of present illness and past medical history are crucial in determining the most probable cause of the heel pain. Upon initial examination, patients are asked to point to the area of maximal tenderness. Patients who present with plantar fasciitis usually complain of pain localized to the plantar medial aspect of the heel along the insertion of the plantar fascia (Buchbinder, 2004; Cole, Seto, & Gazewood, 2005; Dyck & Boyajian-O'Neill, 2004; McPoil et al., 2008; Toomey, 2009). The patient is then asked to

describe the nature of the pain. Patients often describe their heel as throbbing, searing, or piercing in nature (Cole et al., 2005) that is nonradiating and without paresthesias (Toomey, 2009). As a clinician, you begin to rule out nerve entrapment disorders when the patient denies any paresthesias or radiation of pain. Some patients will feel as if they are "walking on a stone" or have a "bruising heel pain" (LaPorta & LaFata, 2005).

Plantar fasciitis frequently has a gradual, insidious onset with acute onsets being far less common (Dyck & Boyajian-O'Neill, 2004; LaPorta & LaFata, 2005). Therefore, it is important to note the onset of the pain as it could help to narrow the list of differential diagnoses significantly. Patients should be asked of any history of trauma to the area, especially if the onset is acute, as this could point to a calcaneal stress fracture or plantar fascia rupture. Patients should be asked if the pain is worse at certain points during the day or if it is persistent and unrelenting. Typical patients with plantar fasciitis often have increased pain with their first several steps in the morning or after periods of prolonged inactivity (Buchbinder, 2004; Cole et al., 2005; Dyck & Boyajian-O'Neill, 2004; LaPorta & LaFata, 2005; McPoil et al., 2008; Toomey, 2009; ). This condition is referred to as poststatic dyskinesia. In most cases, the patient will have an improvement in symptoms with walking or stretching, but will ultimately worsen toward the end of the day (Buchbinder, 2004; McPoil et al., 2008; Toomey, 2009). Patients should be asked of any scenarios that worsen the pain as patients with plantar fasciitis often admit to having their symptoms exacerbated by walking barefoot (Cole et al., 2005). Patients should be asked of any recent modifications in shoe gear, activity changes, or weight gain as these can often elicit symptoms associated with plantar fasciitis (Buchbinder, 2004).

It is of important to note whether the patient has experienced pain in one heel or both. Plantar fasciitis is dominantly present unilaterally with bilateral involvement occurring only 30% of the time (Toomey, 2009). However, in cases where bilateral presentation is evident, then systemic arthropathies such as ankylosing spondylitis, reactive arthritis/Reiter's disease, and psoriatic arthritis must be considered (Buchbinder, 2004; Cole et al., 2005; Neufeld & Cerrato, 2008). The past medical history should be reviewed with the patient, especially any history of rheumatological disorder to aid in ruling out any concerns for infection, seronegative arthropathies, and rheumatoid arthritis.

## Clinical Examination

After acquiring a history of the present illness and a past medical history of the patient, we begin our physical examination by means of a systematic approach. The physical examination begins by observing the patient's gait. Patients may exhibit an antalgic gait as they attempt to favor the unaffected foot (Toomey, 2009; Buchbinder, 2004). The patient may not be able to bear weight on the affected foot, which would lead to suspicion of a calcaneal stress fracture, bone contusion, or plantar fascial rupture. If any of these differential diagnoses are suspected, then additional diagnostic tests will be indicated. In addition, the patient may be obese.

Those with an elevated body mass index place excessive stress on the plantar fascia, especially in those who spend most of the day on their feet (Cole et al., 2005; LaPorta & LaFata, 2005; McPoil et al., 2008). Finally, observe the shoe gear the patient presents in. Inappropriate shoe gear that does not provide adequate heel and arch support has been determined to be a risk factor for plantar fasciitis (LaPorta & LaFata, 2005).

During the physical examination, palpation of the foot and more specifically areas that correlate with plantar fasciitis are performed. The most common clinical correlation indicative of plantar fasciitis is a localized area of maximal tenderness at the medial calcaneal tubercle (Buchbinder, 2004; Cole et al., 2005; LaPorta & LaFata, 2005; McPoil et al., 2008; Neufeld & Cerrato, 2008; Toomey, 2009). Direct palpation of this area elicits the pain experienced by patients after long periods of weight bearing or periods of rest. To thoroughly investigate the integrity of the plantar fascia, the function must also be assessed which is accomplished by performing the Windlass Test. The Windlass test applies a dorsiflexory force to the hallux resulting in plantarflexion of the first metatarsal, effectively increasing the arch of the foot, making the medial band of the plantar fascia taut. Palpation is then performed along the plantar fascial bands, which may further confirm the diagnosis of plantar fasciitis if any of the bands are painful to palpation, especially the medial band. Palpation is performed along the insertion of the Achilles tendon to rule out insertional Achilles tendonitis. The foot and more specifically the heel itself are evaluated for any bruising or edema that could indicate traumatic incident, which would lead to consideration of a bone contusion or plantar fascial rupture. Also, the plantar fat pad or lack thereof should be evaluated.

Next, range of motion of the joints of the foot are performed, particularly range of motion of the ankle joint. An additional finding that has been correlated with plantar fasciitis is the presence of equinus (a short, or tight Achilles tendon) (Buchbinder, 2004; Dyck & Boyajian-O'Neill, 2004; LaPorta & LaFata, 2005; McPoil et al., 2008; Neufeld & Cerrato, 2008; ). More objectively, David D. Dyck noted that ankle dorsiflexion of 10 or less degrees, beyond forming a right angle between the lower leg and foot, as the most important independent risk factor in the development of plantar fasciitis. Compensation for equinus is achieved by evert the subtalar joint during weight bearing that increases tensile load on the plantar fascia, possibly exacerbating or creating the patient's presenting symptoms (Dyck & Boyajian-O'Neill, 2004). Observation of the patient weight bearing may reveal a pronated or cavus foot type.

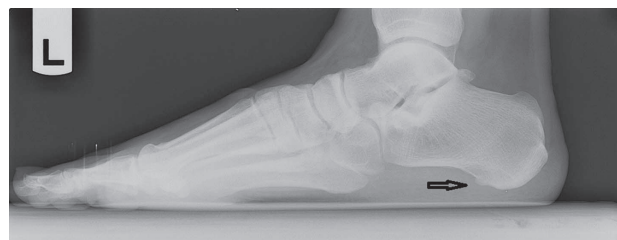Calcaneal stress fracture is a differential diagnosis of concern with heel pain and must be evaluated during physical examination, a negative heel squeeze test should be observed. A compressive force is applied on the calcaneus from lateral to medial, which will elicit pain in the presence of a calcaneal stress fracture. The absence of such pain tentatively rules out stress fracture pending future radiographic studies (Toomey, 2009). Another condition that must be considered because of anatomical proximity is tarsal tunnel syndrome. This is

a condition where the tibial nerve becomes entrapped by the flexor retinaculum of the tarsal tunnel. Percussion, along the medial ankle, produces a radiating pain either distally or both proximally and distally, known as Tinel's or Valleix's sign, respectively. It is among general consensus that plantar fasciitis does not yield radiating pain or signs of paresthesia and therefore produces a negative Tinel's and Valleix's (Toomey, 2009; Neufeld & Cerrato, 2008; McPoil et al., 2008; Buchbinder, 2004). Several tiers of the pedal examination have been discussed to determine pertinent positives that guide a diagnosis of plantar fasciitis. Pertinent negatives are of equal importance as they allow a physician to build confidence in a particular diagnosis, or refute it and begin searching for other causative conditions. As mentioned previously, heel pain is a common complaint among patients and, therefore, other possibilities must be ruled out to further confirm a diagnosis of plantar fasciitis.

## Diagnostics

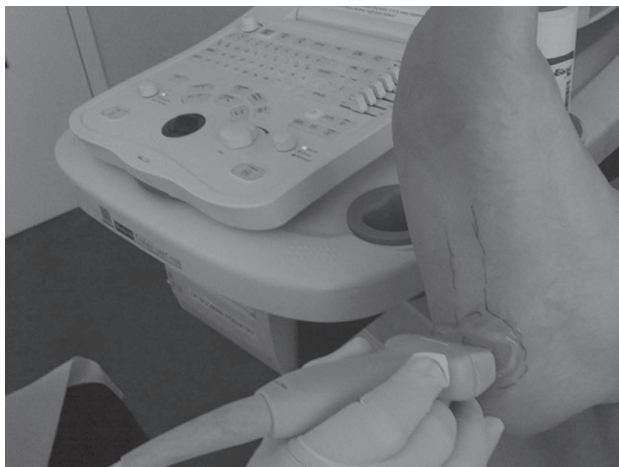Diagnostic modalities may be used when proper history and physical evaluation results are inconclusive. Select imaging studies are beneficial when ruling out other differential diagnoses of heel pain as well as contributing supportive evidence toward the diagnosis of plantar fasciitis. Radiography, bone scan, magnetic resonance imaging (MRI), and ultrasonography comprise the most common studies ordered by physicians when assessing heel pain.

Radiographs are a valuable tool in ruling out acute osseous abnormalities that cause heel pain such as calcaneal stress fractures (Lawrence et al., 2013). A lateral radiograph of the foot (see Figure 1) to assess soft tissue changes should be the first choice if imaging is desired (McPoil et al., 2008). Radiographs can identify a pronated foot type (i.e., pes planus), which has been shown to correlate with chronic heel pain (Irving, Cook, Young, & Menz, 2007). Routine radiographs have been shown to provide no real benefit in diagnosis or treatment in patients with plantar heel pain (Levy, Mizel, Clifford, & Temple, 2006) unless an unusual presentation such as a positive heel squeeze test or history of trauma is noted (Toomey, 2009). As is common with stress fractures, radiographs are limited in their ability to identify fractures in the early stages as fracture lines may not be evident for several weeks. An MRI or bone scan would likely be indicated at this point. Radiographic evidence of heel spurring along the plantar aspect of the calcaneal tuberosity is a prospective finding in patients with plantar fasciitis (see Figure 1). Although there is a slightly increased incidence of heel spurs in patients



**FIGURE 1.** Lateral radiograph with small calcaneal spur.





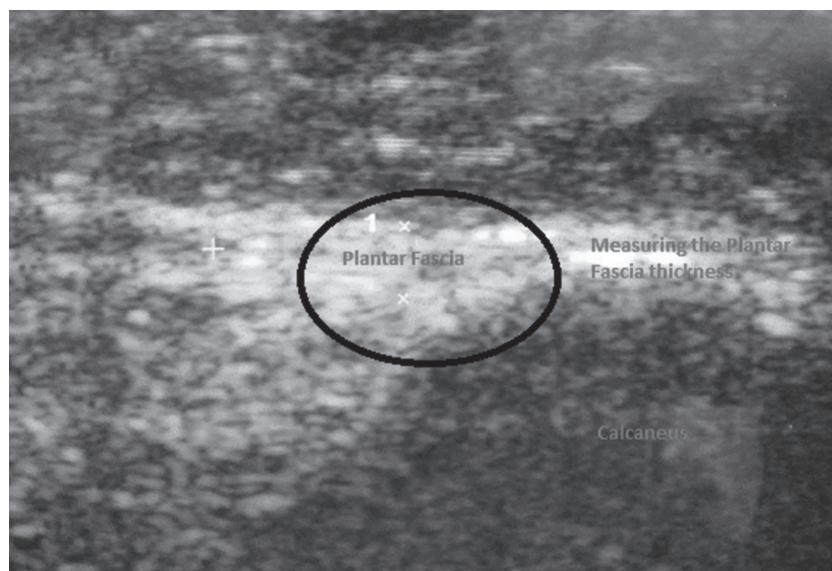
**FIGURE 2.** Ultrasound of plantar fascia performed in office.

with symptomatic plantar fasciitis, it is becoming a general consensus that the pain associated with plantar fasciitis has a weak, if any, correlation to the presence of heel spurring (Healey & Chen, 2010; Toomey, 2009). This belief brings criticism to the widely accepted synonymy between plantar fasciitis and “heel spur syndrome,” which now appears to be quite misleading. Other radiographic findings that can be seen with heel pain are bone tumors, bone cysts, periostitis, and erosions due to infection of rheumatologic causes (Healey & Chen, 2010).

Triphasic bone scans use technetium-99 and are a sensitive but nonspecific imaging technique. In assessing heel pain, they are thought to be most beneficial when differentiating between plantar fasciitis and calcaneal stress fractures. In a stress fracture, there will be diffuse, intense increased activity whereas plantar fasciitis will show focal uptake of in the area of the medial calcaneal tuberosity due to chronic periostitis and inflammation (Healey & Chen, 2010). Bone scintigraphy can rule out infections in the foot such as osteomyelitis.

Magnetic resonance imaging is considered vastly superior to other imaging modalities in terms of its soft-tissue contrast resolution when evaluating plantar fasciitis (Lawrence et al., 2013). Magnetic resonance imaging is ideal when surgical correction is warranted as magnetic resonance findings can be helpful in presurgical planning (Lawrence et al., 2013). Typical magnetic resonance findings present in plantar fasciitis include marrow edema in the calcaneal tuberosity, intrafascial and perifascial edema on T2-weighted images, and fusiform plantar fascial thickening (Lawrence et al, 2013). Normal ranges of plantar fascial thickness vary among the literature, but it is regarded as a general consensus that 2–4 mm would constitute a normal range (Buchbinder, 2004). Patients with plantar fascia thickness exceeding 4 mm are considered to be abnormal and were symptomatic (Healey & Chen, 2010). In addition, magnetic resonance imaging can be used to identify plantar fascia ruptures, which appear as a partial or complete disruption of the fascia with associated edema and hemorrhage on T2 or STIR images (Lawrence et al., 2013). Ruptures occur as a result of strenuous pedal activity or as result of repeated corticosteroid injections when treating chronic plantar fasciitis (Lawrence et al, 2013). Magnetic resonance imaging is useful in ruling out other causes of heel pain such as Achilles tendinosis, Achilles tendon tears, Achilles paratendinitis, retrocalcaneal bursitis, Haglund’s deformity, calcaneal apophysitis, calcaneal stress fractures, and Os trigonum syndrome (Lawrence et al., 2013).

Ultrasound is thought to be as effective as MRI or bone scan in diagnosing plantar fasciitis (Toomey, 2009). The fact that it is noninvasive, readily available, and inexpensive makes it a great alternative to other imaging modalities. Many physician offices may have an ultrasound machine on site (see Figure 2). A normal plantar fascia tends to be hyperechoic and isoechoic with adjacent fat (Healey & Chen, 2010). Sonographic findings of fusiform thickening and hypoechoic (darkened) fascia were deemed to be diagnostic of plantar fasciitis (Karabay, Toro, & Hurel, 2007). As noted



**FIGURE 3.** Ultrasound measurement of plantar fascia.

previously, normal plantar fascia thickness is approximately 2–4 mm (see Figure 3). Ultrasonography can be used to assess the thickness and echogenicity of the plantar fat pad, although Karabay and colleagues determined that these findings were not diagnostic of plantar fasciitis. High-resolution ultrasound can help physicians determine their course of treatment for plantar fasciitis based on sonographic findings. Patients with perifascial edema on ultrasound benefited from corticosteroid injections, whereas those lacking perifascial edema had a better outcome with extracorporeal shock-wave therapy (Sorrentino et al., 2008). Ultrasound may additionally be used in the treatment of plantar fasciitis when used for ultrasound-guided steroid injections.

## Treatment

Now that plantar fasciitis has been diagnosed, how do we treat it? Plantar fasciitis is usually considered to be a self-limiting condition, but there are many treatment modalities ranging from conservative measures to surgical management. Conservative therapies are the mainstay of treatment, beginning with patient-directed therapies then progressing to physician-prescribed modalities, and improve the condition in 90% of patients (Goff & Crawford, 2011). Surgical interventions are reserved for chronic or recalcitrant cases of plantar fasciitis and are required only in about 1% of patients suffering from plantar fasciitis (Cutts et al., 2012).

One of the first-line treatments of plantar fasciitis is rest and oral analgesics such as acetaminophen and nonsteroidal anti-inflammatory drugs. Oral steroids such as a Medrol dose pack may be used to treat plantar fasciitis symptoms, but nonsteroidal anti-inflammatory drugs and analgesics are used on a more frequent basis. A small, randomized placebo-controlled study of nonsteroidal anti-inflammatory drugs to treat plantar fasciitis showed short-term improvement in pain relief and disability when accompanied by other conservative treatments (Goff & Crawford, 2011). Analgesics have not been proven to improve plantar fasciitis symptoms when used as the only treatment.

Stretching is another early treatment for plantar fasciitis. Stretching of the gastroc-soleal complex (Achilles tendon) and/or plantar fascia is indicated. There are many stretching techniques used in various combinations. In one study, at 8 weeks there was improvement in 52% of patients stretching only the plantar fascia and 22% of patient stretching only the gastroc-soleal complex (Healey & Chen, 2010). There is no definitive amount of time that should be dedicated to stretching each day, but increased amount of time spent stretching generally correlates with greater improvement of symptoms.

Night splints are another form of treatment that essentially is used for prolonged stretching. They are worn at night and keep the ankle in a neutral or slightly dorsiflexed position. This prevents nocturnal contraction of the plantar fascia and promotes stretching of the Achilles tendon. Healey and Chen 2010 relay studies on the effectiveness of night splints and all patients in the study experience substantial relief, with an average time

to resolution of 12.5 weeks. A disadvantage to night splints is that they may be uncomfortable to some people and disrupt sleep.

There is a taping method utilized for treatment of plantar fasciitis called a low-Dye taping. This taping helps immobilize the foot and decrease the distance between the origin and insertion of the plantar fascia and thus relieve fascia strain (Healey & Chen, 2010). It is a good indicator of the efficacy of orthotics for treatment of a patient's plantar fasciitis symptoms. The low-Dye taping may provide temporary relief of mild to moderate heel pain but is an ineffective monotherapy for chronic plantar fasciitis (Goff & Crawford, 2011). If a low-Dye taping relieved a patient's plantar fasciitis symptoms, orthotics are indicated for the long-term treatment. There are prefabricated orthotics that may be utilized or a patient can be casted for custom-molded orthotics. Many studies have shown effectiveness to be similar between prefabricated and custom-molded orthotics. Prefabricated orthotics will be much less expensive than the custom-molded orthotics. For custom-molded orthotics, a patient is first cast in office using either plaster or foam box most commonly, but there are other materials that may be used. During the casting, the patient's subtalar joint is held in a neutral position and the midtarsal joint is maximally pronated. This will allow the custom orthotic to hold the patient's foot in a neutral position during gait to decrease tension on the plantar fascia.

There are modifications that can be made to a custom orthotic to help achieve better relief of plantar fasciitis symptoms. A high medial flange may be added to increase motion control at the medial plantar area of the arch of the orthotic (Cox & Cox, 2013). A plantar fascia groove may be added as a concavity on the medial aspect to accommodate the inflamed medial band of plantar fascia (Cox & Cox, 2013). A groove may be added to the heel portion of the orthotic to offload any undue stress caused by plantar calcaneal spurring (Cox & Cox, 2013). A medial heel skive may be added to essentially lift the medial aspect of the heel cup to bring the heel to a more neutral position (Cox & Cox, 2013). These are the most common orthotic modifications used when treating plantar fasciitis.

As stated before, corticosteroids may be given orally to treat the symptoms of plantar fasciitis. A local injection of corticosteroids may be used, too, after other conservative measures have failed. The plantar fascial injection usually consists of a local anesthetic and corticosteroid mix that is injected into the heel at the point of maximum tenderness usually either medially or at times plantarly. Generally, most physicians perform only a limited number of corticosteroid injections per year, depending on the patient's response to the injections. Limited evidence supports the use of corticosteroid injections to manage plantar fasciitis. There is a Cochrane study that proved corticosteroids did help manage plantar fasciitis symptoms at 1 month but not at 6 months when compared to control groups (Cole et al., 2005). Injections should be used with caution because they are associated with plantar fascia rupture and plantar fat pad atrophy.

In recent years, other injectables have been utilized to try to manage plantar fasciitis. Hyperosmolar dextrose (prolotherapy), whole blood, platelet-rich plasma, and onabotulinumtoxin A (Botox) are being investigated as treatment options (Goff & Crawford, 2011). A few small studies have proven these other injectable options as effective, but there is no concrete evidence to prove that they are more effective than a corticosteroid injection. Platelet-rich plasma is the most promising of these alternatives and a randomized controlled trial is under way to determine whether platelet-rich plasma is effective in treating plantar fasciitis.

Additional conservative methods and adjuncts may include immobilization, ice, formal physical therapy, and shoe gear modification. A physician may consider placing the patient in an immobilizing device, such as a CAM walking boot, to rest the area for a short time period. Ice may be used to the plantar heel for 10–15 minutes, depending on your patient's neurological and vascular status. Some physicians recommend massage to the heel. Examples of devices that a patient could use at home to massage the area include a frozen water bottle, which incorporates the icing, and a golf ball. A physical therapy consult may be considered for additional stretching techniques and instruction as well as other modalities that the physical therapist may use during sessions. Shoe modification may also be considered depending on the patient's shoe gear to a more stable and supportive shoe.

Extracorporeal shockwave therapy is another newer therapy being used in the treatment of plantar fasciitis. Extracorporeal shockwave therapy is used to promote neovascularization to aid in healing the degenerative tissue found in plantar fasciitis (Goff & Crawford, 2011). This treatment option is noninvasive and offers hope for a faster recovery time. The adverse effects of extracorporeal shockwave therapy are pain during and after the treatment, ecchymosis to therapy site, and numbness with dysesthesia (Goff & Crawford, 2011). At this time, there are conflicting studies to the effectiveness of extracorporeal shockwave therapy as a treatment of plantar fasciitis.

Fasciotomies (transection of fascia) may be performed and allow for release of the tight plantar fascial bands. Generally, only the medial and central bands of plantar fascia are released and the lateral band is left intact. An open plantar fasciotomy may be performed with an incision typically placed along the plantar medial aspect of the heel just distal to the origin of the plantar fascia on the calcaneal tubercle. Risks of open surgery include about one in four patients still experiencing pain and an overrelease of fascia leading to flat foot (Healey & Chen, 2010). An advantage to an open procedure is allowing resection of a calcaneal spur if one is present. Removal of the spur is not warranted, though, as a cadaveric study was performed that found about half the cases of plantar fasciitis with a bone spur present, the bony spur was not in the same layer as the plantar fascia (Cutts et al., 2012). An endoscopic plantar fasciotomy has become more popular because of its minimally invasive nature and visualization of plantar fascial bands. Complications and recovery times are greatly reduced compared to those of an

open procedure. One of the most common complications that may arise from an endoscopic procedure is sural neuritis at the lateral port. Care must be taken to avoid this important neural structure. There is a higher satisfaction rate in patients receiving an endoscopic procedure versus an open procedure (Healey & Chen, 2010).

Finally, cryosurgery and radiofrequency nerve ablation are much less commonly used procedures to alleviate plantar fasciitis symptoms. Cryosurgery utilizes subfreezing temperatures to produce analgesic effects. A 3-minute freeze 30-second thaw cycle is used during this procedure. Studies are still being performed to assess the effect on nerve and soft tissue structures after the freeze–thaw cycles (Healey & Chen, 2010). Radiofrequency ablation utilizes heat around the tip of an electrode to ablate the nerves that are thought to be the source of plantar fasciitis pain. Very few studies have been performed to assess the effectiveness of this therapy for treatment of plantar fasciitis (Healey & Chen, 2010).

There are multiple treatment modalities available for the treatment of plantar fasciitis ranging from conservative to surgical in nature. In a high percentage of patients, conservative therapy is sufficient to alleviate the symptoms of plantar fasciitis. Surgical therapy is reserved for chronic cases of plantar fasciitis. No one treatment has been proven more effective than another and usually a combination of different therapies is utilized for successful treatment of plantar fasciitis.

## Conclusion

Plantar fasciitis is a common diagnosis in a patient who enters the office, urgent care, or emergency department with heel pain. Within the nursing profession, a nurse or nurse practitioner will invariably come in contact with a patient who relates foot pain, specifically heel pain, and should be aware of the diagnosis of plantar fasciitis and what aspects of the history and examination they will participate in. Plantar fasciitis has a multifactorial etiology. A thorough history and physical examination should be performed to confirm the diagnosis and to rule out any differential diagnoses. At times, additional diagnostic testing may be required and useful in your evaluation of suspected plantar fasciitis. Once the diagnosis of plantar fasciitis is made, there is a multitude of treatment options. Conservative treatment therapies are very effective in relieving the pain and only in a small number of the patient population is surgical treatment indicated. Recurrence of plantar fasciitis may occur, but during our literature search we did not find a statistical analysis of how often and when. Recurrence is likely associated with the risk factors mentioned initially, such as increased weight gain, changes in activity, or shoe gear as well as the other risk factors listed. Prevention of recurrence lies in continued stretching exercises, shoe modifications to a more stable and supportive shoe, and wearing orthotics if they were prescribed in initial treatment. A patient with a recurrence may need additional treatment modalities as well. Plantar fasciitis has a multifactorial etiology with many treatment options with no treatment option




standing above the rest. Conservative treatment is successful in the majority of cases. The practitioner and the patient must work together to diagnose and appropriately resolve plantar fasciitis.

## REFERENCES

- Buchbinder, R. (2004). Clinical practice: Plantar fasciitis. *New England Journal of Medicine*, 350(21), 2159–2166.
- Cole, C., Seto, C., & Gazewood, J. (2005). Plantar fasciitis: Evidence-based review of diagnosis and therapy. *American Family Physician*, 72(11), 2237–2242.
- Cox, D., & Cox, K. (2013). *Cast correction & mold design*. Cox Orthotic Lab. Retrieved October 20, 2013, from <http://www.coxorthotics.com>
- Cutts, S., Obi, N., Pasapula, C., & Chan, W. (2012). Plantar fasciitis. *Annals of The Royal College of Surgeons of England*, 94(8), 539–542.
- Dyck, D. D., Jr. & Boyajian-O'Neill, L. A. (2004). Plantar fasciitis. *Clinical Journal of Sports Medicine*, 14(5), 305–309.
- Goff, J. D., & Crawford, R. (2011). Diagnosis and treatment of plantar fasciitis. *American Family Physician*, 84(6), 676–682.
- Healey, K., & Chen, K. (2010). Plantar fasciitis: Current diagnostic modalities and treatments. *Clinical Podiatric Medical Surgery*, 27(3), 369–380.
- Irving, D. B., Cook, J. L., Young, M. A., & Menz, H. B. (2007). Obesity and pronated foot type may increase the risk of plantar heel pain: A matched case-control study. *BMC Musculoskeletal Disorders*, 8, 41.
- Karabay, N., Toro, T., & Hurel, C. (2007). Ultrasonographic evaluation in plantar fasciitis. *Journal of Foot and Ankle Surgery*, 46(4), 442–446.
- LaPorta, G. A., & LaFata, P. C. (2005). Pathologic conditions of the plantar fascia. *Clinical Podiatric Medical Surgery*, 22(1), 1–9.
- Lawrence, D. A., Rolen, M. F., Morshed, K. A., & Moukaddam, H. (2013). MRI of heel pain. *American Journal of Roentgenology*, 200(4), 845–855.
- Levy, J. C., Mizel, M. S., Clifford, P. D., & Temple, H. T. (2006). Value of radiographs in the initial evaluation of non-traumatic adult heel pain. *Foot and Ankle International*, 27(6), 427–430.
- McPoil, T. G., Martin, R. L., Cornwall, M. W., Wukich, D. K., Irrgang, J. J., & Godges, J. J. (2008). Heel pain—plantar fasciitis: clinical practice guidelines linked to the international classification of function, disability, and health from the orthopaedic section of the American Physical Therapy Association. *Journal of Orthopaedic & Sports Physical Therapy*, 38(4), A1–A18.
- Neufeld, S. K., & Cerrato, R. (2008). Plantar fasciitis: evaluation and treatment. *Journal of the American Academy of Orthopedic Surgery*, 16(6), 338–346.
- Orchard, J. (2012). Plantar fasciitis. *British Medical Journal*, 345. doi:10.1136/bmj.e6603
- Sorrentino, F., Iovane, A., Vetro, A., Vaccari, A., Mantia, R., & Midiri, M. (2008). Role of high-resolution ultrasound in guiding treatment of idiopathic plantar fasciitis with minimally invasive techniques. *La Radiologica Media*, 113(4), 486–495.
- Toomey, E. P. (2009). Plantar heel pain. *Foot and Ankle Clinics*, 14(2), 229–245.

For 90 additional continuing nursing education activities on quality improvement topics, go to [nursingcenter.com/ce](http://nursingcenter.com/ce).

Bimonthly: ISSN 0744-6020



To SUBSCRIBE, CALL 1-800-638-3030  
OUTSIDE THE US (301)223-2300

DF/BG F3NBK881 AIK882Z

## ORTHOPAEDIC NURSING IS ACTIVELY SOLICITING MANUSCRIPTS

*Orthopaedic Nursing*, Official Journal of the National Association of Orthopaedic Nurses, is soliciting manuscripts for publication in the only international journal focusing on orthopaedic nursing care.

### TOPICS OF INTEREST INCLUDE:

- Evidence-based practice
- Case management issues
- Research
- Pediatric, Adult and Geriatric topics
- Orthopaedic Trauma, Oncology, and Infection
- Practice Setting Issues in the Operating Room, Ambulatory setting and Hospital
- Management and Leadership issues.
- Sports Medicine

### FOR FURTHER INFORMATION, PLEASE CONTACT

MARY FAUT RODTS, DNP, CNP, ONC, FAAN

Rush University College of Nursing  
600 S. Paulina Room 1072A  
Chicago, Illinois 60612  
E-mail: [onjeditor@aol.com](mailto:onjeditor@aol.com)

*Orthopaedic Nursing* is now indexed by ISI/Thomson Scientific. Data is being accumulated for calculation of Impact Factor which will be published in the 2007 Journal Citation Report.