

Acne Vulgaris: Clinical Aspects and Treatments

Ryan Geng, MSc, Medical Student, Temerty School of Medicine, University of Toronto, Ontario, Canada.

R. Gary Sibbald, MD, MEd, FRCPC (Med, Derm), FAAD, MAPWCA, JM, Professor, Dalla Lana School of Public Health & Division of Dermatology, Department of Medicine, University of Toronto



GENERAL PURPOSE: To review the clinical presentation and treatment of acne vulgaris.

TARGET AUDIENCE: This continuing education activity is intended for physicians, physician assistants, nurse practitioners, and registered nurses with an interest in skin and wound care.

LEARNING OBJECTIVES/OUTCOMES: After participating in this educational activity, the participant will:

1. Identify a differential diagnosis of acne vulgaris.
2. Recognize clinical feature of various acne vulgaris subtypes.
3. Specify epidemiologic characteristics of acne vulgaris.
4. Select topical, systemic, and nonpharmaceutical treatment options for a patient with acne vulgaris.

ABSTRACT

Acne vulgaris is a common chronic skin condition characterized by variable combinations of papules, pustules, cysts, and nodules that invariably arise from comedones. This article focuses on the clinical presentation of acne vulgaris subtypes and treatment options. Other related topics discussed include epidemiology and differential diagnoses.

KEYWORDS: acne, antibacterial therapies, anticomedytic therapies, anti-inflammatory therapies, comedonal acne, nodulocystic acne, papulopustular acne

ADV SKIN WOUND CARE 2024;37:67-75.

DOI: 10.1097/ASW.000000000000089

INTRODUCTION

Acne vulgaris is a common chronic skin condition affecting the pilosebaceous unit. With an estimated prevalence of 9.4% globally, it is the eighth most common disease worldwide. Acne vulgaris most commonly affects adolescents, with a male predominance, who often exhibit greater severity.¹ Acne may present with noninflammatory (comedones) and inflammatory (papules, pustules, cysts, nodules) components.² Its pathogenesis typically begins in early puberty but can persist into adulthood. It is believed to be triggered by increased keratinization, inflammation, and follicular colonization by *Cutibacterium acnes* (formerly known as *Propionibacterium acnes*) in a sebum-rich environment provided by elevated circulating levels of dehydroepiandrosterone.^{2,3}

The eruption of acne lesions tends to correlate with pilosebaceous unit density. As such, acne is commonly observed in the upper body, particularly the face, chest, and back.³ Given that these areas are very visible, the persistence of acne lesions can result in a profound psychosocial impact, especially in warmer climates where humidity can worsen acne. Many patients with acne experience anxiety, depression, social withdrawal, and anger, and these feelings may be exacerbated when treatments do not produce satisfactory results.⁴

Because of the profound psychosocial impact that acne can have during adolescence, a time when personal

All authors, faculty, and staff have no relevant financial relationships with any ineligible organizations regarding this educational activity. To earn CME credit, you must read the CME article and complete the quiz online, answering at least 8 of the 10 questions correctly. This continuing educational activity will expire for physicians on January 31, 2026, and for nurses March 6, 2026. All tests are now online only; take the test at <http://cme.lww.com> for physicians and www.NursingCenter.com/CE/ASWC for nurses. Complete NCPD/CME information is on the last page of this article.

Downloaded from <http://journals.lww.com/advskw> by 74K41Y3JaeNTM0kvrmpoFtMgeYVnBLMO+0GSESVK0daWU
D+YIHbYuecIDCPRFEq9b9leVUS5SsTJfMOCSCSg40HF7v0PFRzKCGQWNSITBNTGKwQok0H+6zFhUJKUSW9x+UNRduJBRWVp
mC95/53j8HUMFpYXRy6TDkDINpMjNk3zY383eCdhZKra on 01/20/2024

identity and self-esteem development are particularly important, early and appropriate intervention is key. Prompt intervention can also prevent disease progression and scarring associated with more severe outbreaks of acne. When counseling patients, take a patient-centered approach: consider impacts on their activities of daily living and psychosocial well-being and assess their available support systems, financial constraints, and ability to access care. Providing education and support is key to promoting treatment adherence.

CLINICAL FEATURES

Although endocrinologic tests are available for evaluating androgen levels, testing is not standard or recommended for most patients.⁵ Instead, diagnosis relies on patient history and observation of acne lesions in pilosebaceous dense regions.⁶ The types of lesions observed may vary, but acne vulgaris begins with the appearance of comedones, which occur from clogging of the pilosebaceous follicles with sebum and dead skin. Closed comedones are referred to as whiteheads because of their color and are formed when the follicle is fully blocked. Open comedones are referred to as blackheads; because the follicle is incompletely blocked, this leads to the accumulation of oxidized melanin that takes on a dark color.⁷

The types of lesions observed in acne can be grouped based on the severity of the lesions; higher classes are more severe (Table 1). Note that acne presents with polymorphic lesions, and lesions from different classes can co-occur. Although there is currently no standard for assessing the severity of acne, more robust models take into account the number and type of lesions and their bodily distribution.⁸ Classifying the type and severity of acne informs appropriate treatment regimens.

The clinical features of acne can appear similar to several other dermatoses. To aid in distinguishing acne from differential diagnoses, a summary of differential diagnoses with features similar to and different from acne is provided in Table 2. Acne may also present concurrently with these other skin conditions.

ACNE VULGARIS SUBTYPES

Presentations of acne vulgaris subtypes are provided in Figure 1.

Comedonal Acne (Noninflammatory)

Also referred to as acne comedonica, this subtype presents with a pattern of acne in which most of the lesions are comedones. This subtype tends to appear earlier in girls than boys. Comedones typically first appear on the nose before spreading to the forehead, cheeks, and chin and, in some cases, also the trunk. Comedones first appear as closed comedones before enlarging to become open comedones. Although comedones are noninflammatory, closed comedones may rupture and lead to development of inflammatory lesions. Some patients may produce only a few comedones that resolve on their own, whereas other patients may develop scarring inflammatory lesions. However, early intervention can prevent inflammatory lesions from developing.⁷

Papulopustular Acne (Inflammatory)

Also referred to as acne papulopustulosa, this is the most common subtype of acne vulgaris. Here, comedones and inflammatory papules and pustules are all present, with comedones preceding the inflammatory lesions. Papules and pustules may appear in any region where comedones are present, including the neck and trunk. Papules and pustules can resolve without visible scarring. However, deeper and larger lesions (nodules or cysts) may leave easily visible scars that can even be hyperpigmented, especially in patients with darker skin.^{9,10}

Nodulocystic Acne (Inflammatory)

As the severity of acne lesions progresses, cysts and nodules may form, which are inflammatory lesions that are deeper in the skin. Cysts are pus-filled and tend to be softer in texture compared with the firmer and often painful nodules. Nodulocystic acne is the most severe subtype of acne vulgaris, and in severe cases of nodulocystic acne, lesions may coalesce to form larger lesions and sinus tracts. Scarring is commonly observed in this subtype.¹¹

Pain is usually not a symptom of acne except with deeper nodulocystic acne. Some patients with acne fulminans can have fevers, joint pains, and other systemic symptoms. Patients may have painful menses, which may need to be corrected with hormone or other therapies to relieve the pain and subsequently improve living with significant/severe acne.

Acne conglobata. Acne conglobata is a severe form of nodulocystic acne that may have an abrupt onset, but lacks systemic symptoms.¹¹ It is more common in men, especially those with large sebaceous glands and oily skin, and will typically not resolve itself for several years. The defining characteristic of acne conglobata is the presence of large, dome-shaped nodules that often fuse to form larger lesions that may involve draining sinuses. These nodules invariably leave scars after they resolve, which typically takes months. Variable numbers

Table 1. CLASSIFICATION OF ACNE BY TYPE OF LESIONS

Class	Lesions Present
1	Open or closed comedones (noninflammatory)
2	Pustules (inflammatory/superficial)
3	Papules (inflammatory/deep)
4	Cysts or nodules (inflammatory)



Table 2. DIFFERENTIAL DIAGNOSES OF ACNE VULGARIS

Differential Diagnoses	Features Common to Acne	Differences From Acne
Acneiform eruptions	Papules, pustules	No comedones (eg, rosacea)
Acne keloidalis nuchae	Papules, pustules	Only affects nape of neck and occipital scalp, no comedones, often deeper lesions that are firm or fluctuant, +/- pain
Drug-induced acne	Papules, pustules, cysts, nodules	Often monomorphic pustular (eg, systemic prednisone, no comedones). History of androgen, adrenocorticotropic hormone, corticosteroid, bromide, oral contraceptive, lithium, phenytoin, isoniazid, or iodide usage
Immunosuppression-associated eosinophilic folliculitis	Papules, pustules	History of immunosuppression (eg, HIV); intense itchiness
Hidradenitis suppurativa	Papules, pustules, cysts, nodules	Boils, double comedones, sinus tracts, foul smell, tends to localize to intertriginous regions (+ under breasts in females)
Periorificial dermatitis	Papules, pustules	Localized to chin and nasolabial folds, usually no comedones
<i>Pityrosporum folliculitis</i>	Papules, pustules	Itchy, monomorphic, can occur anywhere there are hair follicles. May also have fine scale and pigmentary changes elsewhere. Fluoresces with Wood's light (white-yellow).
Papulopustular rosacea	Papules, pustules	No comedones, usually exclusively centropacial, may present with ocular manifestations, flushing, or enlarged nose
Seborrheic dermatitis	Comedones, papules, pustules	Itchy, greasy yellow scales, dandruff, dyspigmentation. May coexist with rosacea.

of papules and pustules may also be observed. Interestingly, acne conglobata differs from other types of acne in that it is usually less severe in the facial regions, but more commonly affects the trunk, especially the back. It may even spread outside of the usual acne-prone areas, developing in less common areas including the buttocks and thighs.¹²

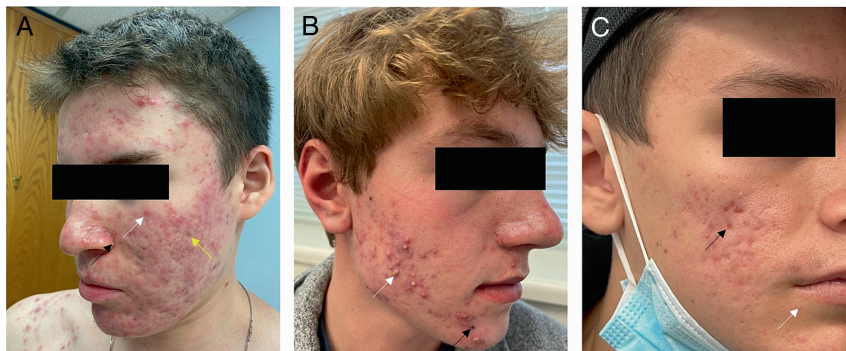
In rare occasions, acne conglobata may occur with hidradenitis suppurativa, dissecting cellulitis of the scalp, and pilonidal sinus simultaneously or at different times of life. This is a severe condition referred to as the follicular occlusion tetrad, and one or more of these four conditions may occur in the same patient. These four conditions share common features, including pilosebaceous gland

hyperplasia, double comedo formation, follicular orifice occlusion, suppuration, and cicatricial scar healing.¹³ Patients often experience great physical and psychological disturbance from the formation of painful cysts, exudation of pus, sinuses, and scars. In severe cases with extensive scarring and keloid formation, surgical management and appropriate wound care are required.

Acne fulminans. Although rare, acne fulminans is the most severe acne subtype and is characterized by sudden onset of cystic and nodular lesions. It is most common in adolescent boys with prior mild to moderate acne. Upon onset, coalescence of lesions is rapid and results in complex, painful, bleeding lesions that can ulcerate, resulting in profound scarring. Osteolytic bone lesions

Figure 1. EXAMPLES OF PAPULOPUSTULAR AND CYSTIC ACNE

A, Papulopustular acne extending past the facial region (see right shoulder) with papules (white arrow), pustules (black arrow), and postinflammatory erythema (yellow arrow). B, Cystic acne with cysts (white arrow) and open comedones (black arrow). C, Papulopustular acne with closed comedones (white arrow), hypotrophic scarring, and postinflammatory erythema (black arrow).



All patients featured in the photographs provided written informed consent for their publication.

may also be present. Unlike acne conglobata, systemic symptoms are involved in acne fulminans and may include fever, malaise, and muscle and joint pain.¹¹

Truncal Acne

As the name suggests, truncal acne affects the chest and back, with lesions ranging from comedones to inflamed papules, pustules, and nodules. As a result of the greater focus on visible facial acne, truncal acne is often clinically underappreciated, even though most epidemiology studies report truncal acne in 50% of patients with facial acne.¹⁴ Thus, when assessing a patient with facial acne, it is important to also examine for truncal involvement.

ACNE VULGARIS TREATMENTS

Acne onset peaks during adolescence, a period when patients become more self-conscious regarding their appearance. As a result, patients may develop unrealistic treatment expectations. Counsel patients on the importance of patience and consistency in applying their treatment regimen and practicing skin hygiene. Patients can also be counseled on making lifestyle changes that may improve their acne. Randomized controlled trials and epidemiology studies have reported factors that exacerbate acne, including a diet containing high amounts of high glycemic index foods, dairy, and meat products and smoking and nicotine use.¹⁵ Sun protection should also be advised as many acne medications increase photosensitivity (especially tetracyclines).

The following discussion focuses on pharmaceutical topical and systemic treatment options available for acne vulgaris, although physical modalities including acid peels, photodynamic therapy, and 1,726-nm lasers (eg, AviClear, Cutera; Accure, Accure Acne) can also be effective treatment options. Treatments are summarized in Table 3. A treatment algorithm is provided in Figure 2.

Topical Treatments

Topical antiandrogen. Clascoterone is an androgen receptor antagonist available (US and Canada) in a 1% cream formulation that is a relatively new agent in the treatment of acne vulgaris for patients older than 12 years. In a trial involving 1,440 patients in two randomized groups, 18.4% and 20.3% of patients treated with clascoterone 1% cream for 12 weeks achieved clear or almost clear on the Investigator's Global Assessment scale compared with 9% and 6.5% for vehicle ($P < .001$). Clascoterone is generally well tolerated, with the most common adverse reactions being nasopharyngitis, headache, and oropharyngeal pain.¹⁷

Topical antibiotics. Clindamycin and erythromycin are the most common topically applied antibiotics for the treatment of acne; their efficacy results from their antibacterial and anti-inflammatory properties. Clindamycin is

Table 3. TREATMENTS USED IN THE MANAGEMENT OF ACNE VULGARIS

Treatment Type	Treatments (Alphabetical Order)
Topical	Azelaic acid Benzoyl peroxide ^a Clascoterone Clindamycin ^{a,b} Dapsone ^c Erythromycin ^{a,b} Minocycline Retinoic acid ^{a,c} Salicylic acid
Systemic	Combination oral contraceptives ^b Isotretinoin ^{d,e} Macrolides ^b Azithromycin Erythromycin Spironolactone Tetracyclines ^b Doxycycline Minocycline Sarecycline Tetracycline
Physical	1,726-nm laser Chemical peel Photodynamic therapy

First-line treatments:

^aMild-moderate papulopustular acne without scarring.

^bModerate papulopustular acne with scarring.

^cComedonal acne.

^dNodulocystic acne.

^eAcne fulminans.

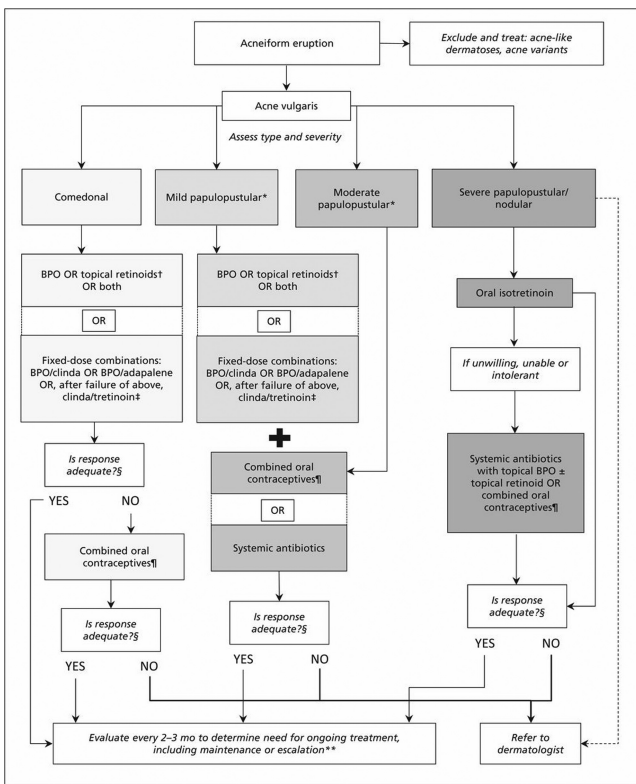
available in 1% formulations, and erythromycin is available in 2% formulations. Clindamycin is preferred because erythromycin has a greater risk of resulting in bacterial resistance.¹⁸ Because of increasing rates of antibiotic resistance to clindamycin and erythromycin, a topical minocycline 4% foam has recently been developed, with demonstrated efficacy in clinical trials.¹⁹ As a tetracycline, minocycline is also less susceptible to resistance than clindamycin and erythromycin.¹⁹ The most common adverse reactions include redness, dryness, and itchiness.

Antibiotic monotherapy is not advised because of the risk of developing bacterial resistance. To mitigate this risk, antibiotics are often used with benzoyl peroxide; combination products are available with stable mixtures of antibiotic and benzoyl peroxide or vitamin A derivatives.⁵ In one trial, patients who applied clindamycin 1%/benzoyl peroxide 5% combination gel once daily for 11 weeks showed a 61% reduction in inflammatory lesions compared with 5% for placebo ($P < .002$) and a 36% reduction in noninflammatory lesions compared with an 11% reduction for placebo ($P < .004$).²⁰ The most common adverse reactions include dryness, scaliness, and peeling.



Figure 2. TREATMENT ALGORITHM

A treatment algorithm for acne based on subtype and severity. Adequate clinical responses to treatment should be monitored and evaluated every 2 to 3 months to determine need for ongoing, maintenance, or escalation of treatment.



Abbreviation: BP, benzoyl peroxide.

*Combination products.

**Only for females.

Reproduced from Asai et al.¹⁶

Topical azelaic acid. Azelaic acid is a mild antibacterial, anti-inflammatory, and comedolytic agent that is applied topically in the form of 15% or 20% formulation. It is typically an adjunctive treatment for acne, especially in treating post-inflammatory hyperpigmentation,⁵ but it has demonstrated efficacy as a monotherapy as well. In one study, patients who applied azelaic acid 20% gel twice daily for 45 days showed a 60% reduction in total lesions compared with 20% for placebo ($P = .002$).²¹ Adverse reactions include dryness, stinging, and burning.

Topical benzoyl peroxide. Benzoyl peroxide is an antibacterial agent that has mild comedolytic properties, with formulation strengths ranging from 2.5% to 10%. It is an effective monotherapy for mild acne and is often recommended for patients on antibiotics therapy, either topical or oral, to prevent bacterial resistance.^{5,22} In one trial, patients who applied benzoyl peroxide 5% gel once daily for 3 months showed a 77% reduction in inflammatory lesions compared with 43% for placebo ($P < .001$)

and a 70% reduction in noninflammatory lesions compared with 23% for placebo ($P < .001$).²³ Benzoyl peroxide is routinely combined with clindamycin topically; although *C. acne* often develops resistance to clindamycin, it will still be susceptible to benzoyl peroxide. Clindamycin also provides an anti-inflammatory effect that helps reduce irritation from the benzoyl peroxide component.

Inform patients that benzoyl peroxide bleaches fabric, to expect temporary contact irritation, and to cease use if the irritation becomes severe. Adverse reactions include contact allergic dermatitis, dryness, erythema, stinging, and burning.

Topical dapsone. Dapsone is an anti-inflammatory agent that is particularly effective in treating inflammatory acne lesions and is more effective in women than in men and adolescents.⁵ In one study, patients who applied dapsone 7.5% gel once daily for 12 weeks showed a 55% reduction in inflammatory lesions compared with 48% for vehicle ($P < .001$) and a 45% reduction in non-inflammatory lesions compared with 39% for vehicle ($P < .001$).²⁴ Inform patients that the coapplication of dapsone with benzoyl peroxide can result in oxidation, leaving a brown/orange discoloration of the skin that can be washed off. Adverse reactions of dapsone include itching, dryness, burning, and erythema.

Topical retinoids. Retinoids are vitamin A derivatives that have anti-inflammatory properties. However, it is their potent comedolytic properties and their ability to resolve precursors of comedones that make them a core therapy of acne and maintenance after clearance. As a result, retinoids are recommended as a monotherapy for comedonal acne and in combination with other treatments for inflammatory acne. The most commonly used retinoids in the treatment of acne are tretinoin, tazarotene, and adapalene, all of which are available in various concentrations. In one trial, patients who applied tretinoin 0.05% gel once daily for 90 days showed a 77% reduction in total lesions compared with 22% for placebo ($P = .001$).²⁵ Because of the irritation caused by retinoids, advise patients to apply retinoids less frequently initially before progressing to once-daily applications. Adverse reactions include dryness, itching, and burning. These adverse effects may be mitigated with less-frequent applications, shorter contact time, and using oil-free noncomedogenic moisturizer 5 to 10 minutes after application.

Topical salicylic acid. Salicylic acid is a comedolytic agent commonly found in over-the-counter antiacne products, with strengths varying between 0.5% and 2%.⁵ In one study, patients who applied salicylic acid 2% lotion twice daily for 12 weeks showed significant reductions in both inflammatory ($P = .022$) and non-inflammatory ($P < .001$) lesions.²⁶ However, these products have mostly been replaced by more advanced

Downloaded from http://journals.lww.com/ascwjournal by 74K41Y3JasNT1W0kxmpofMgeiVWnBLMO-0G6SVKQdaJWJ mC95f53j8HUMFpYXRy6TDKd1NpMjIK3zY383c6CHZKra on 01/20/2024

topical options, as described previously. Adverse reactions include stinging, dryness, and itching.

Systemic Treatments

Antibiotics. Systemic antibiotics are first-line treatments for moderate to severe forms of inflammatory acne that are recalcitrant to topical therapy. Because of the risk of developing resistance, antibiotic treatment length should be kept as short as possible and be used in conjunction with benzoyl peroxide. Benzoyl peroxide or retinoids are also suggested for maintenance after completion of systemic antibiotic therapy.⁵

Tetracyclines. Tetracyclines, including tetracycline, doxycycline, and minocycline, are a family of bacteriostatic anti-inflammatory agents. Tetracyclines are the preferred option for systemic antibiotic therapy because of the lower risk of developing bacterial resistance.⁵ Interestingly, tetracyclines have demonstrated efficacy even at sub-antimicrobial doses. In one study, patients who took doxycycline 20 mg twice a day (BID) for 6 months showed a 54% reduction in noninflammatory lesions compared with 11% for placebo ($P < .01$) and a 50.1% reduction in inflammatory lesions compared with 30% for placebo ($P = .04$).²⁷ Tetracyclines are not safe for use in children younger than 8 years or in pregnant or lactating individuals.

Doxycycline 100 mg BID provides useful antibacterial coverage, including against community-acquired methicillin-resistant *Staphylococcus aureus*. Long-term usage is often administered for scarring acne when patients either are not candidates for or choose to avoid oral isotretinoin. Doxycycline at subantimicrobial doses of 40 mg daily has the advantage of not altering the gut flora. Doxycycline 40 mg is available in North America, but it is expensive and may not be covered under drug plans. Doxycycline in the pill form is preferred over capsules to reduce the risk of esophagitis. Because of photosensitivity, doxycycline is best taken after 4 PM in the summer months. It can be taken with the evening meal because its absorption is reduced only by 20% with food or milk, or 1 hour prior to bed with a full glass of water.

Sarecycline is the newest tetracycline class of antibiotic approved for treatment of acne. In one trial involving 2,002 patients in two groups, 21.9% and 22.6% of patients treated with sarecycline 1.5 mg/kg per day achieved clear or almost clear on the Investigator's Global Assessment scale compared with 10.5% and 15.3% for placebo.²⁸ However, sarecycline is much more expensive than other tetracyclines.

Macrolides. Macrolides, including azithromycin and erythromycin, are bacteriostatic agents with anti-inflammatory properties. Although macrolides are effective, they are typically used only in the treatment of acne in patients for whom tetracyclines are contraindicated (eg, during

pregnancy, in children <8 years old) because of the higher risk of developing resistance. For this reason, erythromycin is not recommended.⁵ In one trial, patients who received azithromycin 500 mg three times per week for the first month, 250 mg three times per week for the second month, and 250 mg two times per week for the third month were compared with patients who took doxycycline 100 mg daily for 3 months. Azithromycin was as effective as doxycycline ($P = .771$), with the 3-month inflammatory lesion count being reduced by 90% in the azithromycin group ($P < .001$) and by 88% in the doxycycline group ($P < .001$).²⁹ Adverse reactions are typically gastrointestinal, including diarrhea and epigastric burning.

Hormonal agents

Combination oral contraceptives. Combination oral contraceptives (COCs) contain both estrogen and progestins, with efficacy in treating acne by lowering androgen levels in women. They can be used effectively in conjunction with other acne therapies, especially in patients presenting with additional signs indicative of a hormonal etiology, including hirsutism. However, advise patients that acne improvement with COCs is gradual and typically takes at least three monthly treatment cycles.⁵ In one trial, patients taking ethinyl estradiol 0.03 mg/chlormadinone acetate 2 mg for six cycles saw a 55% decrease in noninflammatory lesions compared with 32% for placebo ($P < .001$) and a 64% reduction in inflammatory lesions compared with 45% for placebo ($P = .03$).³⁰ Screen patients for safety, because COC use increases the risk of breast cancer, myocardial infarction, and venous thrombotic events, along with other adverse events.³¹

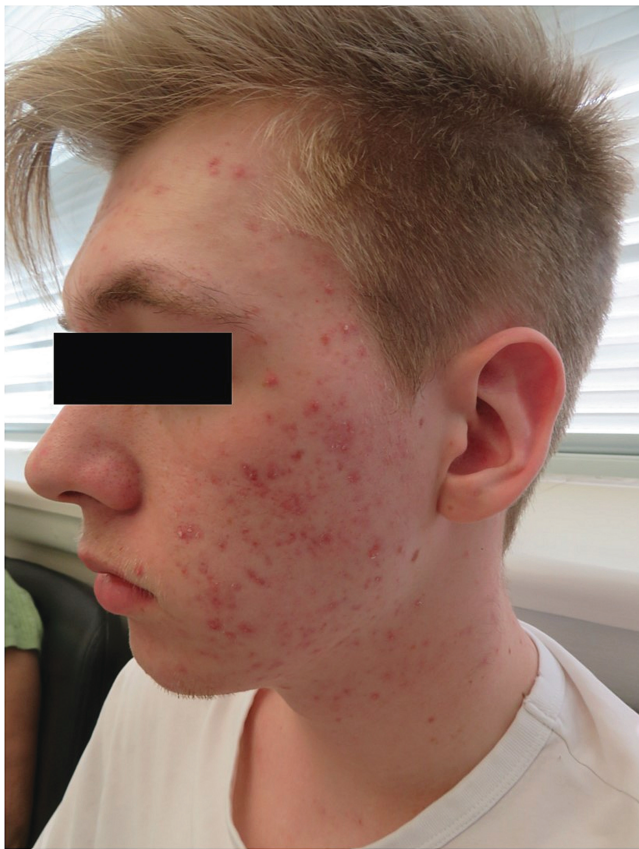Spirolactone. Spirolactone is an aldosterone antagonist that has a diuretic with BP-lowering properties, but also exhibits antiandrogenic effects. Although effective in treating acne, it is not recommended for men because of the high risk of developing gynecomastia. Larger clinical trials assessing its efficacy are also lacking. In one retrospective study, of patients who took spironolactone 50 to 100 mg daily for up to 24 months, 33% cleared, 33% had marked improvement, and 27% had partial improvement.³² Spirolactone is not recommended as a first-line treatment because of frequent adverse reactions including menstrual breakthrough bleeding, amenorrhea, discharge from breasts, and dizziness (which may be attributed to decreased BP).³³

Isotretinoin. Isotretinoin is a vitamin A derivative used for the treatment of severe nodulocystic acne or acne that is recalcitrant to other forms of topical or systemic therapies. As a potent teratogen, patients of child-bearing potential must use two forms of contraceptives prior to starting isotretinoin. Advise menstruating patients to start isotretinoin on



Figure 3. CASE 1

Man with moderate papulopustular acne involving the forehead, cheeks, chin, neck, and upper chest.



Case 1

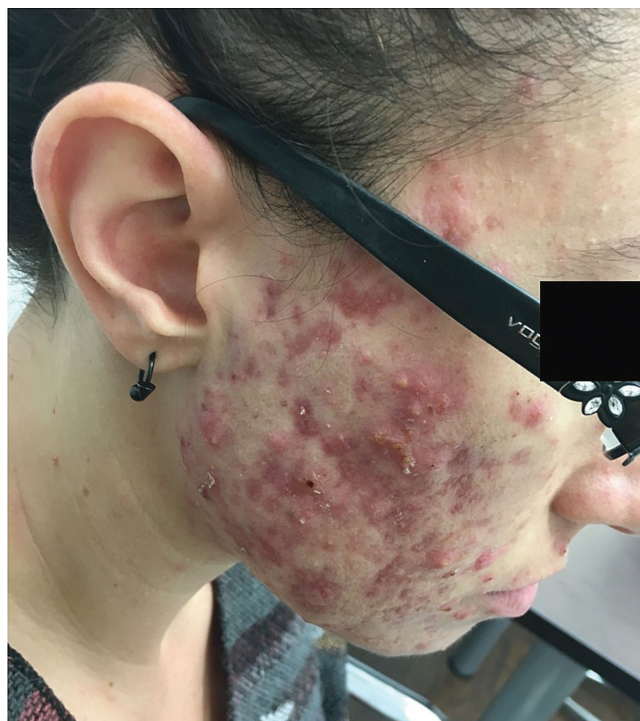An 18-year-old man presented with moderate papulopustular acne with forehead, cheeks, neck, and upper chest involvement ongoing for 2 years (Figure 3). He was previously prescribed topical benzoyl peroxide 5% combined with clindamycin in a 1% gel by his family physician with slight improvement noted. Given the inadequate response to topical therapy alone, the authors started him on doxycycline 100 mg BID to be taken with dinner (food will decrease absorption by approximately 20%) and at bedtime with a full glass of water, along with topical adapalene 0.1%/benzoyl peroxide 2.5% gel. The provider recommended that the patient take the doxycycline later in the day to avoid photosensitivity. Response will be assessed in 3 months. Laboratory tests will be monitored monthly. Roughly 25% of individuals may experience a transient increase in cholesterol, with other adverse effects (low white blood cell count) being less common.

Case 2

A 23-year-old woman presented with severe nodulocystic acne, mainly involving the cheeks and temples, ongoing for 3 years (Figure 4). She was previously prescribed topical benzoyl peroxide 5% gel, topical tretinoin 0.05% cream, azithromycin 500 mg, and various over-the-counter facial washes and spot treatments containing salicylic

Figure 4. CASE 2

Woman with severe nodulocystic acne involving the cheeks and temples.



the second day of their menstrual period. Isotretinoin is best absorbed when taken with food. In one trial, patients receiving an average maximum isotretinoin dosage of 1.2 mg/kg per day saw a 32% reduction in cystic lesions after 2 months compared with an increase of 58% for placebo ($P < .008$).³⁴ Adverse reactions include skin dryness, headaches, and muscle aches. Monitoring of cholesterol, triglycerides, and liver function is advised until response to treatment is achieved.

Isotretinoin is typically dosed at 0.5 to 1.0 mg/kg per day. However, because adverse reactions are dose-dependent, lower doses may be recommended to reduce the risk. In a prospective study, patients treated with a lower isotretinoin dose (0.3–0.4 mg/kg per day) for 3 months demonstrated a significant reduction in severity grade of acne ($P < .0001$).³⁵ Some clinicians aim for 120 mg cumulative/kg total body weight. Thus, for a 70-kg patient, a cumulative dose would be 8,400 mg (210 × 40-mg capsules).

EXAMPLE CASES

Patients provided consent for their case details and photographs to be published.

acid with limited improvement noted. Given the lack of response and severity of her acne, she decided to start isotretinoin therapy. At 60 kg, her cumulative dose was set at 7,200 mg (120 mg per kg body weight), taking 20-mg capsules twice daily with food for 6 months (360 × 20-mg capsules). She was counseled on the importance of avoiding pregnancy while on isotretinoin and for 1 month after cessation of therapy. She had not been sexually active and elected to continue to abstain from sexual contact until 1 month after discontinuing therapy. A negative pregnancy test was obtained prior to starting isotretinoin, and the capsule was started on the second day of her period. Individuals with child-bearing potential who are sexually active should be on two types of birth control and have monthly pregnancy tests. Providers will assess response to treatment in 6 weeks.

CONCLUSIONS

Acne vulgaris is a common chronic skin condition that impacts most individuals, usually during adolescence. The severity of acne can range from mild cosmetic blemishes in the facial region to painful suppurative lesions over the entire body with systemic symptoms. Several effective topical and systemic pharmaceutical treatments are available to reduce the psychosocial impact of the disease.

PRACTICE PEARLS

- Acne vulgaris consists of several subtypes including comedonal, papulopustular, nodulocystic, and truncal.
- Acne vulgaris is a psychosocially laden disease, with many patients experiencing anxiety, social withdrawal, reduced self-esteem, and depression.
- Acne treatment options are based on acne subtype and severity.
- Effective topical and systemic therapies have anti-comedolytic, antibacterial, or anti-inflammatory properties that target components involved in the pathogenesis of acne.
- The multiple potent properties of oral retinoids (decreased sebaceous gland size and anti-comedolytic, anti-inflammatory, and antibacterial properties) make them a life-changing treatment for patients with moderate to severe acne.


REFERENCES

1. Tan JK, Bhate K. A global perspective on the epidemiology of acne. *Br J Dermatol* 2015;172(Suppl 1): 3-12.

2. Sutaria AH, Masood S, Schlessinger J. *Acne Vulgaris*. Treasure Island, FL: StatPearls; 2023.
3. Williams HC, Dellavalle RP, Garner S. Acne vulgaris. *Lancet* 2012;379(9813):361-72.
4. Thomas DR. Psychosocial effects of acne. *J Cutan Med Surg* 2004;8(4):3-5.
5. Zaengle AL, Pathy AL, Schlosser BJ, et al. Guidelines of care for the management of acne vulgaris. *J Am Acad Dermatol* 2016;74(5):945-73.e33.
6. Titus S, Hodge J. Diagnosis and treatment of acne. *Am Fam Physician* 2012;86(8):734-40.
7. Plewig G, Kligman AM. Acne comedonica (comedonal acne). In: Plewig G, Kligman AM, eds. *Acne and Rosacea*. Berlin, Germany: Springer; 1993:256-61.
8. Witkowski JA, Parish LC. The assessment of acne: an evaluation of grading and lesion counting in the measurement of acne. *Clin Dermatol* 2004;22(5):394-7.
9. Callender VD. Acne in ethnic skin: special considerations for therapy. *Dermatol Ther* 2004;17(2): 184-95.
10. Plewig G, Kligman AM. Acne papulopustulosa (papulopustular acne). In: Plewig G, Kligman AM, eds. *Acne and Rosacea*. Berlin, Germany: Springer; 1993:263-69.
11. Bologna JL, Schaffer JV, Cerroni L. *Dermatology*. Elsevier Health Sciences; 2017.
12. Bluhm C, Hollmann J, Plewig G, Kligman AM. *Acne and Rosacea*. Berlin, Germany: Springer; 2012.
13. Reis AC, Chicarilli Z. Therapeutic options for the follicular occlusion tetrad. *Curr Opin Dermatol* 1995; 2:69-74.
14. Daniele SG, Kim SR, Grada A, Moore AY, Suozzi KC, Bunick CG. truncal acne and scarring: a comprehensive review of current medical and cosmetic approaches to treatment and patient management. *Am J Clin Dermatol* 2023;24(2):199-223.
15. Lynn DD, Umari T, Dunnick CA, Dellavalle RP. The epidemiology of acne vulgaris in late adolescence. *Adolesc Health Med Ther* 2016;7:13-25.
16. Asai Y, Baibergenova A, Dutil M, et al. Management of acne: Canadian clinical practice guideline. *CMAJ* 2016;188(2):118-26.
17. Hebert A, Thiboutot D, Stein Gold L, et al. Efficacy and safety of topical clascoterone cream, 1%, for treatment in patients with facial acne: two phase 3 randomized clinical trials. *JAMA Dermatol* 2020; 156(6):621-30.
18. Mills O Jr, Thornsberry C, Cardin CW, Smiles KA, Leyden JJ. Bacterial resistance and therapeutic outcome following three months of topical acne therapy with 2% erythromycin gel versus its vehicle. *Acta Derm Venereol* 2002;82(4):260-5.
19. Raouf TJ, Hooper D, Moore A, et al. Efficacy and safety of a novel topical minocycline foam for the treatment of moderate to severe acne vulgaris: a phase 3 study. *J Am Acad Dermatol* 2020;82(4): 832-37.
20. Lookingbill DP, Chalker DK, Lindholm JS, et al. Treatment of acne with a combination clindamycin/ benzoyl peroxide gel compared with clindamycin gel, benzoyl peroxide gel and vehicle gel: combined results of two double-blind investigations. *J Am Acad Dermatol* 1997;37(4):590-5.
21. Irajfi F, Sadeghinia A, Shahmoradi Z, Siadat AH, Jooya A. Efficacy of topical azelaic acid gel in the treatment of mild-moderate acne vulgaris. *Indian J Dermatol Venereol Leprol* 2007;73(2): 94-6.
22. Dutil M. Benzoyl peroxide: enhancing antibiotic efficacy in acne management. *Skin Ther Lett* 2010; 15(10):5-7.
23. Kawashima M, Sato S, Furukawa F, et al. Twelve-week, multicenter, placebo-controlled, randomized, double-blind, parallel-group, comparative phase II/III study of benzoyl peroxide gel in patients with acne vulgaris: a secondary publication. *J Dermatol* 2017;44(7):774-82.
24. Thiboutot DM, Kirkic L, McMichael A, et al. Efficacy, safety, and dermal tolerability of dapsone gel, 7.5% in patients with moderate acne vulgaris: a pooled analysis of two phase 3 trials. *J Clin Aesthet Dermatol* 2016;9(10):18-27.
25. Tirado-Sanchez A, Espindola YS, Ponce-Olivera RM, Bonifaz A. Efficacy and safety of adapalene gel 0.1% and 0.3% and tretinoin gel 0.05% for acne vulgaris: results of a single-center, randomized, double-blinded, placebo-controlled clinical trial on Mexican patients (skin type III-IV). *J Cosmet Dermatol* 2013;12(2):103-7.
26. Eady E, Burke B, Pulling K, Cunliffe W. The benefit of 2% salicylic acid lotion in acne a placebo-controlled study. *J Dermatol Treat* 1996;7(2):93-6.
27. Skidmore R, Kovach R, Walker C, et al. Effects of subantimicrobial-dose doxycycline in the treatment of moderate acne. *Arch Dermatol* 2003;139(4):459-64.
28. Moore A, Green LJ, Bruce S, et al. Once-daily oral sarecycline 1.5 mg/kg/day is effective for moderate to severe acne vulgaris: results from two identically designed, phase 3, randomized, double-blind clinical trials. *J Drugs Dermatol* 2018;17(9):987-96.
29. Akhyani M, Ehsani AH, Ghiasi M, Jafari AK. Comparison of efficacy of azithromycin vs. doxycycline in the treatment of rosacea: a randomized open clinical trial. *Int J Dermatol* 2008; 47(3):284-8.
30. Plewig G, Cunliffe WJ, Binder N, Hoschen K. Efficacy of an oral contraceptive containing EE 0.03 mg and CMA 2 mg (Belara) in moderate acne resolution: a randomized, double-blind, placebo-controlled phase III trial. *Contraception* 2009;80(1):25-33.
31. Arrington EA, Patel NS, Gerancher K, Feldman SR. Combined oral contraceptives for the treatment of acne: a practical guide. *Cutis* 2012;90(2):83-90.
32. Shaw JC. Low-dose adjunctive spironolactone in the treatment of acne in women: a retrospective analysis of 85 consecutively treated patients. *J Am Acad Dermatol* 2000;43(3):498-502.
33. Charny JW, Choi JK, James WD. Spironolactone for the treatment of acne in women, a retrospective study of 110 patients. *Int J Womens Dermatol* 2017;3(2):111-5.
34. Peck GL, Olsen TG, Butkus D, et al. Isotretinoin versus placebo in the treatment of cystic acne. A randomized double-blind study. *J Am Acad Dermatol* 1982;6(4 Pt 2 Suppl):735-45.
35. Rao PK, Bhat RM, Nandakishore B, Dandakeri S, Martis J, Kamath GH. Safety and efficacy of low-dose isotretinoin in the treatment of moderate to severe acne vulgaris. *Indian J Dermatol* 2014; 59(3):316.



For more than 170 additional continuing professional development articles related to Skin and Wound Care topics, go to NursingCenter.com/CE.



CONTINUING MEDICAL EDUCATION INFORMATION FOR PHYSICIANS

Lippincott Continuing Medical Education Institute, Inc., is accredited by the Accreditation Council for Continuing Medical Education to provide continuing medical education for physicians.

Lippincott Continuing Medical Education Institute, Inc., designates this journal-based CME activity for a maximum of 1 *AMA PRA Category 1 Credit™*. Physicians should claim only the credit commensurate with the extent of their participation in the activity.

PROVIDER ACCREDITATION INFORMATION FOR NURSES

Lippincott Professional Development will award 2.5 contact hours and 1.5 pharmacology contact hours for this nursing continuing professional development activity.

LPD is accredited as a provider of nursing continuing professional development by the American Nurses Credentialing Center's Commission on Accreditation.

This activity is also provider approved by the California Board of Registered Nursing, Provider Number CEP 11749 for 2.5 contact hours. LPD is also an approved provider of continuing nursing education by the District of Columbia, Georgia, West Virginia, New Mexico, South Carolina, and Florida CE Broker #50-1223. Your certificate is valid in all states.

OTHER HEALTH PROFESSIONALS

This activity provides ANCC credit for nurses and *AMA PRA Category 1 Credit™* for MDs and DOs only. All other healthcare professionals

participating in this activity will receive a certificate of participation that may be useful to your individual profession's CE requirements.

CONTINUING EDUCATION INSTRUCTIONS

- Read the article beginning on page 67. For nurses who wish to take the test for NCPD contact hours, visit www.NursingCenter.com/ce/ASWC. For physicians who wish to take the test for CME credit, visit <http://cme.lww.com>. Under the Journal option, select *Advances in Skin and Wound Care* and click on the title of the CE activity.
- You will need to register your personal CE Planner account before taking online tests. Your planner will keep track of all your Lippincott Professional Development online NCPD activities for you.
- There is only one correct answer for each question. A passing score for this test is 8 correct answers. If you pass, you can print your certificate of earned contact hours or credit and access the answer key. Nurses who fail have the option of taking the test again at no additional cost. Only the first entry sent by physicians will be accepted for credit.

Registration Deadline: January 31, 2026 (physicians); March 6, 2026 (nurses).

PAYMENT

The registration fee for this CE activity is \$24.95 for nurses; \$22.00 for physicians.

Downloaded from <http://journals.lww.com/asn/journal by 744.41.13.14 on 01/20/2024>
 D+YIHbYuecIDCPREFFq9b9leVUxSSaTFMOCSCSg40HfYvPFRZKXGQWN5ITBNTGKwQok0H+H6zPhUKUSW9x+UNRduJBRWVP
 mC95f53j8HUMFpYXRy6TDkDlNpMgNk3zY383eCdhZkra on 01/20/2024